

Abdulkadir KÜÇÜKBAYRAK<sup>1</sup>  
Leyla Yılmaz AYDIN<sup>2</sup>  
Yurdanur ERDOĞAN<sup>2</sup>  
Çiğdem BİBEROĞLU<sup>2</sup>  
Derya HOŞGÜN<sup>2</sup>  
Yetkin AĞAÇKIRAN<sup>3</sup>

İletişim (Correspondance)

Abdulkadir KÜÇÜKBAYRAK  
Atatürk Göğüs Hastalıkları ve Göğüs Cerrahisi Eğitim ve  
Araştırma Hastanesi, Enfeksiyon Hastalıkları ve Klinik  
Mikrobiyoloji Kliniği ANKARA

Tlf: 0312 381 07 20  
e-posta: abdulbayrak@yahoo.com

Geliş Tarihi: 14/05/2010  
(Received)

Kabul Tarihi: 19/12/2010  
(Accepted)

<sup>1</sup> Atatürk Göğüs Hastalıkları ve Göğüs Cerrahisi Eğitim ve  
Araştırma Hastanesi, Enfeksiyon Hastalıkları Ve Klinik  
Mikrobiyoloji Kliniği ANKARA

<sup>2</sup> Atatürk Göğüs Hastalıkları ve Göğüs Cerrahisi Eğitim ve  
Araştırma Hastanesi, Göğüs Hastalıkları Kliniği  
ANKARA

<sup>3</sup> Atatürk Göğüs Hastalıkları ve Göğüs Cerrahisi Eğitim ve  
Araştırma Hastanesi, Patoloji Laboratuvarı ANKARA



CASE REPORT

## CHRONIC NECROTIZING PULMONARY ASPERGILLOSIS IN AN ELDERLY PATIENT WITH ACUTE MYELOID LEUKEMIA-M2 IN REMISSION

### ABSTRACT

This paper presents a case of chronic necrotizing pulmonary aspergillosis (CNPA) in a 61-year-old male patient with acute myeloid leukemia-M2 (AML-M2). The patient was admitted to our clinic with non-productive cough for eight months and hemoptysis for four months. He had been diagnosed with AML-M2 and treated with cytosine-arabioside and idarubicin seven months earlier. Thorax computed tomography (CT) demonstrated bilateral, perivascular, and multiple small nodules as well as multiple thick wall cavitary lesions with irregular margins in the entire lung areas, especially the upper lobes. An open lung biopsy by thoracotomy was performed and mixed inflammatory cells, necrosis (without caseation), multinuclear giant cells, epithelioid histiocytes, and aspergillus hyphae with bronchial wall destruction were seen in biopsy specimens from the right upper lobe. The patient was treated with amphotericin B for three weeks. As a follow-up, itraconazole was administered for a year. The patient is the first case where CNPA along with an overt immune-compromising disease such as AML-M2 has been observed in one patient.

**Key Words:** Leukemia, Myeloid, Acute; Invasive Pulmonary Aspergillosis; Itraconazole; Thoracotomy.



OLGU SUNUMU

## REMİSYONDA AKUT MYELOİD LÖSEMİ-M2'Lİ YAŞLI BİR HASTADA KRONİK NEKROTİZAN PULMONER ASPERGİLLOZİS

### Öz

Biz bu yazıda akut myeloid lösemili-M2 (AML-M2) 61 yaşında bir erkek hastada kronik nekrotizan pulmoner aspergillozis olgusu sunduk. Hasta 8 aydır var olan non-produktif öksürük ve 4 aydır olan hemoptizi şikayeti ile kliniğimize alındı. Hastanın 7 ay önce AML-M2 tanısı aldığı ve sitozin-arabinozid-idarubisin ile tedavi edildiği öğrenildi. Toraks bilgisayarlı tomografisinde her iki akciğer lobunda perivasküler multipl nodüller ve özellikle üst loblarda olmak üzere multipl kalın duvarlı düzensiz sınırlı lezyonlar görüldü. Açık akciğer biyopsisi yapıldı. Biyopsi materyalinin histopatolojik incelemesinde mikst inflamatuvar hücreler, nekroz (kazeifikasyon yok), multinükleer dev hücreler, epitelioid histiositler ve aspergillus hifaları görüldü. Hasta üç hafta boyunca amfoterisin-B ve sonraki bir yıl boyunca itraconazol ile tedavi edildi. Bu vaka AML-M2 gibi aşırı immünyetmezlikli bir hastada sunulan ilk kronik nekrotizan pulmoner aspergillozis vakasıdır.

**Anahtar Sözcükler:** Akut Myeloid Lösemi; M2; Kronik Nekrotizan Pulmoner Aspergillozis; İtraconazol; Torakotomi



## INTRODUCTION

Pulmonary aspergilloma, allergic bronchopulmonary aspergillosis, hypersensitivity pneumonitis, and invasive and semi-invasive necrotizing aspergillosis are among the lung diseases caused by the aspergillus species (1,2). Semi-invasive or subacute invasive aspergillosis such as chronic necrotizing pulmonary aspergillosis (CNPA) was first described by Gefter et al. and Binder et al. in 1981 (2,3). CNPA is an uncommon, cavitary, and infectious process of the lung parenchyma caused by the aspergillus species (2,4). The clinical course of CNPA, unlike invasive pulmonary aspergillosis (IPA), progresses slowly over weeks to months. However, there is usually no dissemination to other organs or vascular invasion. This syndrome has been described in patients with impaired local defences due to lung disease and in those patients who are mildly immunocompromised.

CNPA has received little attention in the literature and very few case reports have been published (3,4). To the best of our knowledge, CNPA in overtly immunocompromised patients with conditions such as leukaemia, neutropenia, and organ transplantation has not been touched in the literature. This is the first known case of CNPA in an overtly immunocompromised patient with leukaemia.

## CASE

A 61-year-old male patient was admitted to our clinic with complaints of non-productive cough for eight months and haemoptysis for four months. His past medical history showed that he had been diagnosed with AML-M2 and treated with cytosine-arabioside and idarubicin chemotherapy seven months earlier. The patient was found to be in remission based on two different bone-marrow biopsies taken at the end of the chemotherapy protocol. He was an ex-smoker with a past smoking history of 20 pack-years. His family history was unremarkable. On his physical examination, lung auscultation revealed expiratory rhonchi in the entire lung areas. The findings of other system examinations were unremarkable.

Laboratory findings on admission were as follows: blood glucose was 143mg/dl, haemoglobin was 10.7g/dL, hematocrit was 31.4%, and red blood cell count was 3.3g/dl. All other routine laboratory findings were within normal limits. The cultures of six sputum samples revealed no bacterial or fungal growth. Furthermore, microscopic examinations of the six sputum samples were negative for Acid Fast Bacilli. A

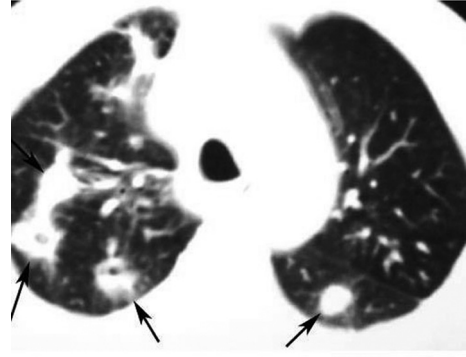


Figure 1

tuberculin skin test of 10mm was performed. Cytomegalovirus (CMV) Ig G was found to be positive while CMV Ig M, the aspergillus skin test, and M3 aspergillus tests were negative. Antinuclear antibody (ANA), Anti ds-DNA, p-ANCA, c-ANCA, C<sub>3</sub>, C<sub>4</sub>, Anti Jo-1, Anti Scl 70, Ig A, M, G values were within the normal ranges.

Thorax computed tomography (CT) demonstrated bilateral, perivascular, and multiple small nodules, and multiple thick wall cavitary lesions with irregular margins in the entire lung area, especially the upper lobes. There were infiltrations with ground-glass opacities in the apex, peribronchial wall thickening in the medial segment of the right middle lobe, and bronchiectasis in the posterior segment of the right upper lobe (Figure 1).

There were no significant findings on fiberoptic bronchoscopy examination, and cytological and microbiological examinations of bronchoalveolar lavage fluid showed no atypical cells, bacteria or fungi.

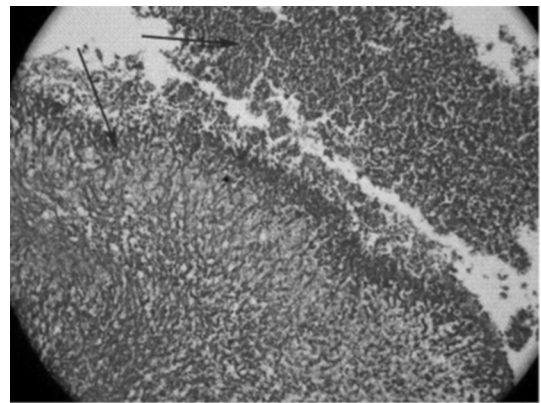
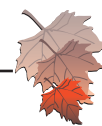


Figure 2



The patient was administered sulbactam-ampicillin (4gr/day) (i.v.). However, clinical and radiological findings at the end of the two weeks showed no improvement. Therefore, open lung biopsy was performed. Mixed inflammatory cells, necrosis (without caseation), multinuclear giant cells, epithelioid histiocytes, and aspergillus hyphae with bronchial wall destruction (Figure 2) were observed in the biopsy specimens from the right upper lobe, and the patient was diagnosed with CNPA. Amphotericine-B 300mg/day treatment was commenced. At the end of the third week of treatment, the amphotericine-B was changed to oral itraconazole 400mg/day. At the end of the 16<sup>th</sup> week of the treatment, a decrease in the number of nodules (only two nodules persisted) and the disappearance of cavitory lesions (Figure 3) were observed on thorax CT examination.

At the end of the 6<sup>th</sup> month, no differences were recognised in the number of nodules on thorax CT compared to thorax CT at the 16<sup>th</sup> week. Therefore, we decided to continue the itraconazole treatment. Induction chemotherapy for cancer was administered at the 9<sup>th</sup> month of itraconazole treatment. The patient was treated with amphotericine-B (300mg/day) for one week during the induction chemotherapy. Antibiotic therapy (itraconazole) was discontinued at the end of the 12<sup>th</sup> month. After that, amphotericine-B for a week and itraconazole for three weeks were delivered only in the course of induction chemotherapies. Because of the benign nature, no invasive diagnostic investigations were planned for these two persistent nodules. During the patient's follow-up,

there was no progression of the disease or nodules even after two years of treatment.

## DISCUSSION

Typically, CNPA occurs in middle-aged and elderly patients with impaired local defence such as chronic pulmonary diseases, pneumoconiosis, cystic fibrosis, radiation therapy, previous pulmonary tuberculosis, lung infraction, thoracic surgery or (less commonly) sarcoidosis. Mildly immunocompromised patients with factors such as chronic liver disease, low dose corticosteroid therapy, diabetes mellitus, alcoholism, connective tissue diseases, and malnutrition (2,5) may also be affected. CNPA is not expected to be observed in patients with haematological malignancies such as leukaemia, neutropenia or in organ transplantation (6). The literature indicates that our case is different from other cases of CNPA as the patient had the overt immune-compromising disease, AML-M2. We think that the CNPA in our patient could not have developed into IPA because AML-M2 had been in remission for six months

Most patients with CNPA present with pulmonary and systemic complaints lasting from one to six months. The symptoms are nonspecific such as cough, sputum expectoration, weight loss, fever, and chest pain. Haemoptysis and dyspnea have also been reported, albeit rarely (4,5). Vascular invasion is the mainstay of haemoptysis in aspergillosis. For this reason, haemoptysis is comparatively less common and less severe in patients with CNPA than in patients with IPA.

The chest X-ray and thorax CT of patients with CNPA generally display consolidation, cavitory lesions, and pleural thickening, especially in the upper lobes (2). These symptoms progress slowly over weeks to months (7).

Aspergillus antibodies have been determined in most of the cases but may be negative in the course of CNPA (8). Although aspergillus skin tests are not diagnostic, they are helpful for differential diagnosis and aspergillus may grow in the culture of sputum and bronchoscopy samples (2,8). In our patient, the aspergillus skin test and M3 aspergillus test were negative and the culture of sputum and bronchoscopy samples were also negative for aspergillus spp.

The growth of aspergillus spp. in culture and histopathological demonstration of tissue invasion by aspergillus spp. are gold standards for diagnosis. The pathology of CNPA is characterized by aspergillus hyphae, necrosis, and acute or chronic inflammation of the lungs (9). However, the tissue cultures of transbronchial biopsy specimens or percutaneous

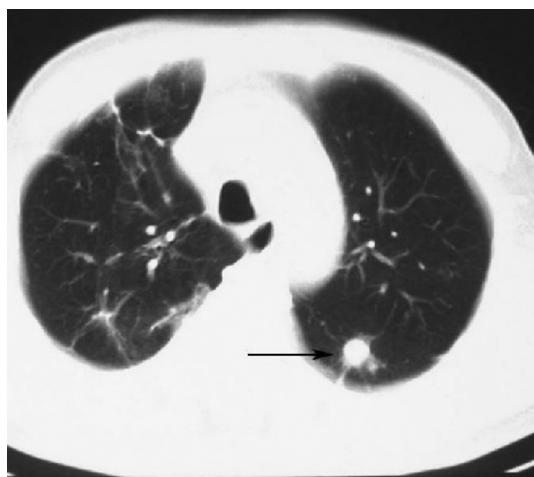

Figure 3



aspirates are relatively poor for aspergillus spp. Open lung or thoracoscopic biopsy are rarely needed in these patients. For this reason, the diagnosis is difficult and usually delayed. However, delayed diagnoses are associated with increased morbidity and mortality. Therefore, early diagnosis entails a high index of suspicion. All of the clinical and radiological findings, positive serological results for aspergillus spp., isolation of aspergillus spp. from respiratory samples, and demonstration of the invasion in the pulmonary tissue with septate hyphae typical to aspergillus spp. by histopathological examination are evaluated for the diagnosis of CNPA (10). Denning et al. have suggested a criteria for earlier diagnosis, therapy, and follow-up in patients with CNPA. They have suggested that a patient should not be diagnosed as CNPA because the condition easily progresses to IPA if a patient has an overt immunocompromising condition (e.g. haematological malignancy, neutropenia or organ transplantation) (10). Flexible bronchoscopic examination of our patient was normal and microbiological examinations of bronchoalveolar lavage fluid revealed no bacterial or fungal growth. Therefore, open lung biopsy was performed and no bacterial or fungal growth was observed in the cultures of tissue biopsy specimens. Finally, the patient was diagnosed with CNPA through histopathological examination.

Antifungal therapy is the first line treatment for patients with CNPA. Amphotericine-B 0.5-1mg/kg/day (4-5 mg/kg/day for the lipid formulation) is administered initially (2,4), and itraconazole is also an effective alternative treatment to the relatively toxic amphotericine-B (4,11). The duration of the antifungal treatment is unclear and depends on the clinical, radiological, and microbiological response of the patient. CNPA may reoccur after the discontinuation of the therapy (12). Our patient was treated with amphotericine-B (5mg/kg/day for the lipid formulation) for the first 15 days. Then, 400mg oral itraconazole was introduced and the treatment was discontinued at the end of 12 months. After this, one week amphotericine-B (5mg/kg/day for the lipid formulation) and three weeks 400mg oral itraconazole was used for induction chemotherapy.

Surgical treatment may be performed for patients with a localized form of the disease or patients unresponsive to antifungal therapy. However, the physicians should be careful during the postoperative period because the rate of complications is very high (12).

This is the first CNPA case report in an overtly immunocompromised patient and CNPA can be determined in overtly immunocompromised patients with conditions such as

leukaemia. The lesions of CNPA can spread through the entire lung area. Open lung biopsy should be performed for differential diagnosis if clinical suspicion is high and the aspergillus skin test, serological tests for aspergillus, and cultures are negative and if bronchoscopic examination is normal. CNPA should be treated over a long period and the treatment duration should be evaluated along with the clinical and radiological situation, and microbiological response. There may be no improvement in some nodular lesions and these patients should be closely followed up. Furthermore, antifungal therapy should be administered again if the patient enters a period of reduced immune responsiveness.

## REFERENCES

1. Gefter WB. The spectrum of pulmonary aspergillosis. *J Thoracic Imaging* 1992;7:56-74. (PMID:1404546).
2. Binder RE, Faling LJ, Pugatch RD, Mahasaen C, Snider GL. Chronic necrotizing pulmonary aspergillosis: a discrete clinical entity. *Medicine (Baltimore)* 1982;61:109-24. (PMID: 7038373).
3. Gefter WB, Weingrad TR, Epstein DM, Ochs RH, Miller WT. "Semi-invasive" pulmonary aspergillosis: a new look at the spectrum of aspergillus infections of the lung. *Radiology* 1981;140: 313-21. (PMID: 7255704).
4. Saraceno JL, Phelps DT, Ferro TJ, Futerfas R, Schwartz DB. Chronic necrotizing pulmonary aspergillosis: approach to management. *Chest* 1997;112:541-8. (PMID: 9266898).
5. Soubani AO, Chandrasekar PH. The clinical spectrum of pulmonary aspergillosis. *Chest* 2002;121(6):1988-99. PMID: 12065367
6. Zmeili OS, Soubani AO. Pulmonary aspergillosis: a clinical update. *QJM* 2007;100(6):317-34. (PMID: 17525130).
7. Kim SY, Lee KS, Han J, Kim J, Kim TS, Choo SW, Kim SJ. Semiinvasive pulmonary aspergillosis: CT and pathologic findings in six patients. *Am J Roentgenol* 2000;174:795-8. (PMID: 10701627).
8. Denning DW. Chronic forms of pulmonary aspergillosis. *Clin Microbiol Infect* 2001;7(Suppl. 2):25-31. (PMID:11525215).
9. Parra I, Remacha A, Rezusta A, et al. Chronic necrotizing pulmonary aspergillosis. *Med Mycol* 2004;42:369-71. (PMID: 15473363).
10. Denning DW, Riniotis K, Dobrashian R, Sambatakou H. Chronic cavitary and fibrosing pulmonary and pleural aspergillosis: case series, proposed nomenclature change, and review. *Clin Infect Dis* 2003;37(Suppl. 3): S265-80. (PMID: 12975754).
11. Caras WE, Pluss JL. Chronic necrotizing pulmonary aspergillosis: pathologic outcome after itraconazole therapy. *Mayo Clin Proc* 1996;71:25-30. (PMID: 8538227).
12. Silva EF, Barbosa Mde P, Oliveira MA, Martins RR, Fontinele e Silva J. Chronic necrotizing pulmonary aspergillosis. *J Bras Pneumol* 2009;35(1):95-8. (PMID: 19219337).