

Gülen DEMİRPOLAT¹
Nurhan SARIOĞLU²
Bahar YANIK¹
Erdoğan BÜLBÜL¹



CASE REPORT

NONTHROMBOTIC PULMONARY ARTERY EMBOLISM IN AN ELDERLY PATIENT: HYDATID CYST

ABSTRACT

Pulmonary artery embolism related to hydatid disease is extremely rare. Although isolated cases have been reported, it is usually due to a hepatic lesion invading the hepatic veins or inferior vena cava, or a direct embolism from right cardiac lesions. Patients may present with hemoptysis, dyspnea, chest pain, acute cor pulmonale, or sudden death. The diagnosis is made from a medical history, clinical findings and computed tomography imaging. The computed tomography shows single or multiple cystic lesions leading to a filling defect or obstruction in the pulmonary arteries. In this article we present a 76-year-old woman with multiple lung lesions and a bilateral pulmonary artery embolism. In this case the pulmonary artery embolism was considered to be secondary to the invasion of the inferior vena cava by the liver lesion.

Key Words: Pulmonary Arteries; Pulmonary Embolism; Hydatidosis; Echinococcosis, Hepatic; Echinococcosis; Pulmonary.



OLGU SUNUMU

YAŞLI BİR HASTADA NONTROMBOTİK PULMONER ARTER EMBOLİSİ: KİST HİDATİK

Öz

Kist hidatiğe bağlı pulmoner arter embolisi çok nadir izlenir. İzole olgular bildirilmiş olsa da, genellikle karaciğerdeki bir lezyonun hepatic venlere veya vena cava inferiora açılmasıyla ya da sağ kalpteki lezyonların embolisiyle oluşur. Hastalar kliniğe hemoptizi, dispne, göğüs ağrısı, kor pulmonale veya ani ölümlerle gelebilir. Tanı öykü, klinik bulgular ve bilgisayarlı tomografi görüntüleme ile koyulur. Bilgisayarlı tomografide pulmoner arterlerde dolum defekti veya tıkanma oluşturan tek veya çok sayıda kistik lezyon saptanır. Bu makalede çok sayıda akciğer lezyonu ve bilateral pulmoner arter embolisi olan 76 yaşındaki kadın hasta sunulmaktadır. Bu olguda pulmoner arter embolisinin vena cava inferiorun karaciğerdeki lezyon tarafından invaze edilmesine bağlı olduğu düşünülmüştür.

Anahtar Sözcükler: Pulmoner Arterler; Pulmoner Emboli; Hidatidozis; Hepatik Ekinokok; Pulmoner Ekinokok

İletişim (Correspondance)

Gülen DEMİRPOLAT
Balıkesir Üniversitesi Tıp Fakültesi Radyoloji Anabilim
Dalı BALIKESİR

Tlf: 0266 612 10 10
e-posta: gulendemirpolat@hotmail.com

Geliş Tarihi: 15/04/2014
(Received)

Kabul Tarihi: 30/06/2014
(Accepted)

¹ Balıkesir Üniversitesi Tıp Fakültesi Radyoloji Anabilim
Dalı BALIKESİR

² Balıkesir Üniversitesi Tıp Fakültesi Göğüs Hastalıkları
Anabilim Dalı BALIKESİR



INTRODUCTION

Echinococcosis is a parasitic disease, endemic in some regions of the world. It is manifested as cystic and solid-appearing masses in virtually any organ. The lung is the second most common site of cyst development after the liver (1). Lung involvement is usually isolated but may be concomitant with liver disease.

A pulmonary artery embolism is an uncommon complication and is caused by the cystic form of echinococcus granulosus. The parasite may reach the pulmonary arteries by the haematogenous route from the liver or it may arise from right cardiac lesions (2). Chest pain, dyspnea, hemoptysis, malaise, fever, acute cor pulmonale, or even sudden death may be seen.

In this article we present a case with bilateral multiple lung lesions related to pulmonary artery embolism with hydatid disease (HD). The patient's chest X-ray and multidetector computed tomography (MDCT) findings are shown.

CASE REPORT

A 76-year-old woman presented with a history of cough (2 years), loss of appetite and weight (6 kg in 3 months). She had been expectorating serous sputum for 2 to 3 months, which had been more mucoid in the last few days. The spu-

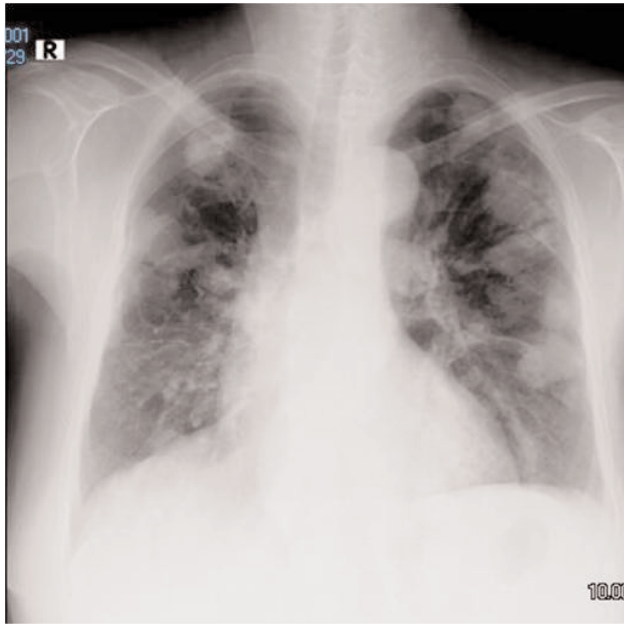


Figure 1— PA chest X-ray showing bilateral and multiple nodular lung lesions.

tum was bloody two times in the week prior to admission. In the past, medical treatment had been recommended because of multiple pulmonary cysts. She had been treated with albendazole for 1.5 years. Unfortunately, she had ceased the therapy 6 months before, when she felt well.

Systemic examination was unremarkable except for pale-ness and diminished breath sounds. Results of laboratory investigations were normal except for elevated CRP (2.79 mg/L) and sedimentation rate (64/hr) levels. Indirect hemagglutination for HD was >1:2560 (+). The chest X-ray showed multiple different sized and shaped nodules with smooth borders distributed in both lungs (Figure 1). Contrast-enhanced MDCT disclosed few cavitory lesions in the upper lung zones and disseminated cystic lesions. Multiple serpentine, cystic lesions were seen in the mid and lower zones of the lungs. Some of them were occluding the branches of the pulmonary arteries and some were arising from the peripheral bronchial carinas and tracking the bronchovascular bundles (Figure 2 A,B,C). On the upper abdominal images, an exophytic partially calcified caudate lobe lesion was seen. It reached the inferior vena cava (IVC) and the right adrenal gland (Figure 3). The IVC was partially occluded with HD.

Albendazole treatment was given to the patient. Lung lesions waned after 2 months of treatment, but she complained of hemoptysis 2 to 3 times. The patient is still in follow-up at our chest disease outpatient clinic.

DISCUSSION

Although pulmonary artery embolisms are usually detected in patients with liver HD, isolated cases have also been reported (3). In all patients with liver lesions located near the IVC and/or hepatic veins, pulmonary artery involvement should be investigated with a systematic search (4). In our patient, an exophytic caudate lobe lesion lead to a pulmonary embolism via IVC. Multiple lung cysts may be associated with pulmonary artery embolism, as in our patient; however, these are not always present.

Three clinical presentations have been described in hydatid cyst-related pulmonary artery embolism: protracted pulmonary hypertension, pulmonary hypertension leading to death within a year, and acute fatal disease related to massive embolism (5). Obliterating cystic lesions or postoperative granulomatous reaction and fibrosis may cause pulmonary hypertension. Early diagnosis and treatment may prevent pulmonary hypertension.

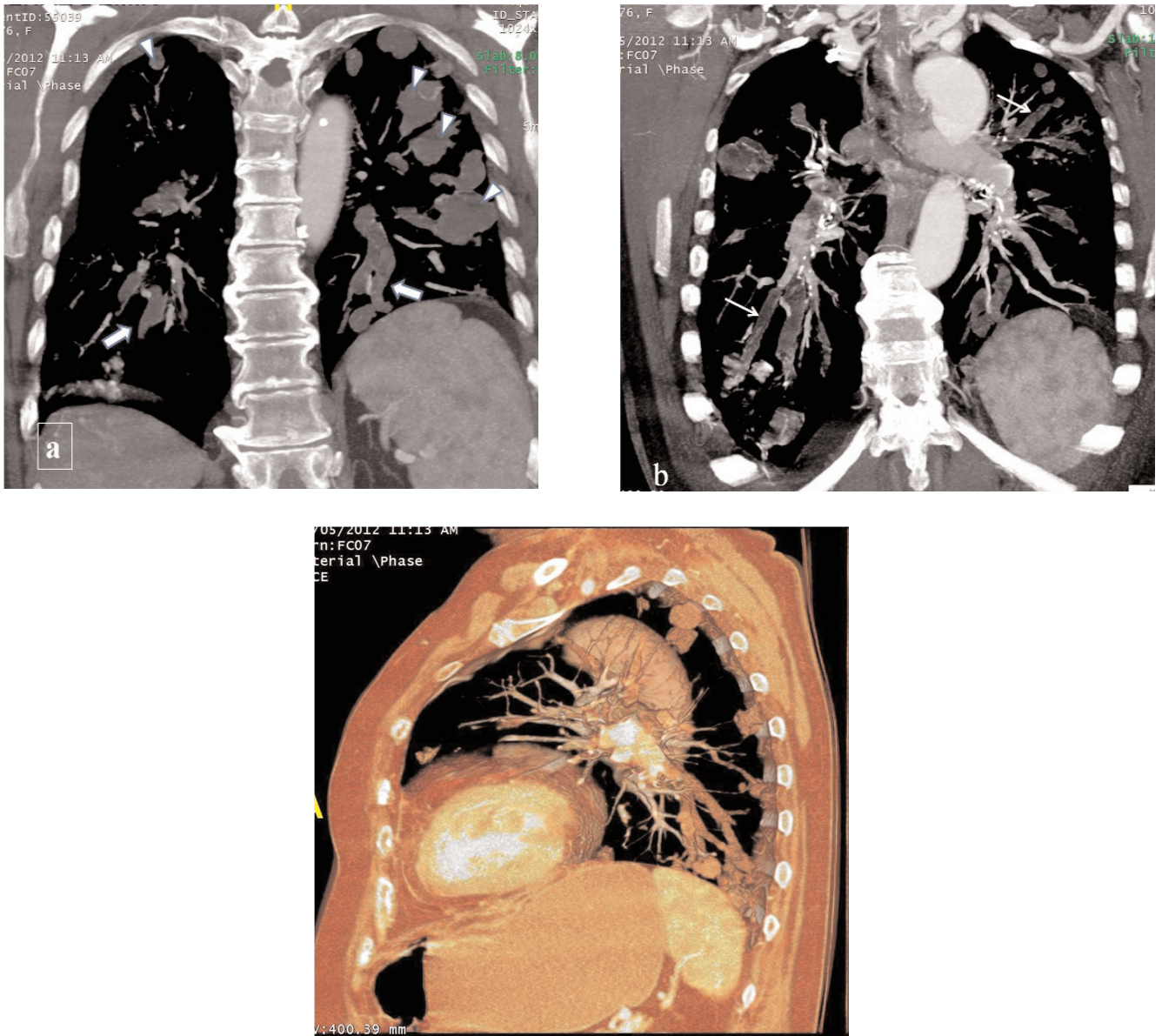


Figure 2— Coronal (A, B) and sagittal (C) reformatted MDCT maximum intensity projection images show low density cystic serpentine lesions (thick arrow) in the mid and lower zones of the lungs. They were occluding the left lung upper lobe and right lung lower lobe segmental pulmonary arteries (thin arrow). In addition several peripheral parenchymal cysts are noted (arrowhead).

The diagnosis of pulmonary artery embolism due to HD depends on clinical and radiological findings. Serologic tests can be used to confirm infection. The most accurate imaging modality is MDCT. It provides volumetric rendering techniques that raise diagnostic capability. Multiplanar reformatted images and three-dimensional reconstructions permit the

exploration of fine anatomical detail and show extensions of the lesions and their relationships with pulmonary arteries. Accompanying heart, lung and liver lesions may be detected in a single scan. On contrast-enhanced MDCT scans, well-defined fluid attenuated cystic structures, partially or totally occluding the main pulmonary arteries with or without its

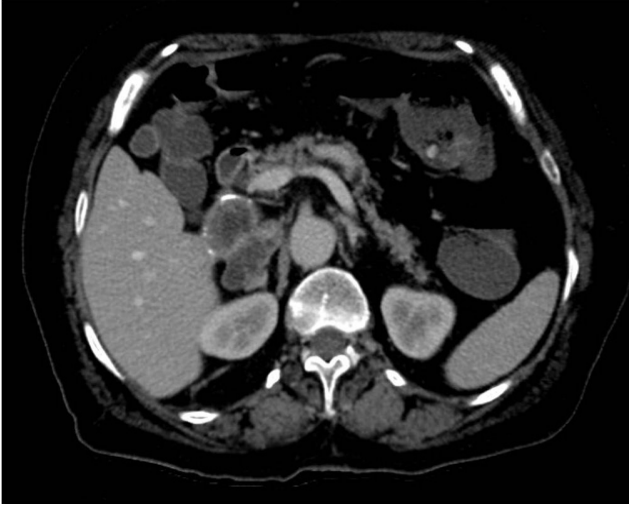

Figure 3— Axial contrast enhanced MDCT image showing partially calcified exophytic liver hydatid cyst protruding and invading the IVC (arrow).

branches, are seen. Intra-arterial lesions may cause enlargement of the vessel and an enhancement of the cyst wall may be detected (1, 6).

Pulmonary thromboembolism, tumor embolism and pulmonary artery sarcoma should be evaluated in the differential diagnosis. Acute thromboembolism may mimic HD embolism with acute onset of chest pain, cough and hemoptysis. It may be excluded with patient's medical history and a cystic filling defect in the pulmonary arteries on MDCT scan. Tumor embolisms usually occur in extrapulmonary malignancies such as sarcoma and breast, gastric, renal cell, prostate, hepatocellular, and choriocarcinoma. The specific signs that indicate tumor emboli in major branches are contrast enhancement within the intra-arterial filling defect and a dilated and beaded appearance of the affected pulmonary arteries (7). Pulmonary artery sarcoma is an aggressive tumor, shows enhancement with contrast agents and almost always has mediastinal or parenchymal invasion when it is detected (1).

In proximal pulmonary intravascular HD, the definitive treatment is excision of the pulmonary artery cyst and if possible extraction of the leading liver lesion. However, this treatment has several life-threatening risks. Patients should be informed about the rupture of the artery and/or the cyst, dissemination of the disease, anaphylactic shock, and pseudoaneurysm formation (2). In disseminated lung lesions and in patients who do not accept surgical intervention, medical therapy should be started.

In conclusion, in patients with pulmonary artery embolism, medical history should be investigated properly and HD should be kept in mind, especially in patients with liver echinococcosis. The definitive diagnosis and the dissemination of the disease can be accurately identified with MDCT.

REFERENCES

1. Damiani MF, Carratù P, Tatò I, et al. Recurrent pulmonary embolism due to echinococcosis secondary to hepatic surgery for hydatid cysts. *J Comput Assist Tomogr* 2012;36(5):534-5. (PMID:22992602).
2. Akgun V, Battal B, Karaman B, et al. Pulmonary artery embolism due to a ruptured hepatic hydatid cyst; Clinical and radiologic imaging findings. *Emerg Radiol* 2011;18(5):437-9. (PMID:21494880).
3. Karantanas AH, Bitsios G, Karaiskou E. Echinococcus of the pulmonary artery; CT, MRI and MRA findings. *Comput Med Imaging Graph* 2000;24(4):265-7. (PMID:10842051).
4. Vinatier I, Rivaud E, Tcherakian C, et al. Nonthrombotic pulmonary embolism. *Eur Respir J* 2010;35(1):224. (PMID:20044467).
5. Bayarogullari H, Davran R, Cavus Y, et al. Liver hydatid cyst leading to bilateral pulmonary artery embolism and bilateral multiple pulmonary echinococcosis via inferior vena cava; Report of a case. *Clin Imaging* 2013;37(2):374-8. (PMID:23465996).
6. Namn Y, Maldjian PD. Hydatid cyst embolization to the pulmonary artery; CT and MR features. *Emerg Radiol* 2013;20(6):565-8. (PMID:23686588).
7. Pena E, Dennie C, Franquet T, Milroy C. Nonthrombotic pulmonary embolism; A radiological perspective. *Semin Ultrasound CT MR* 2012;33(6):522-34. (PMID:23168062).