

GIANT CELL REPARATIVE GRANULOMA ASSOCIATED WITH MANDIBULAR FRACTURE IN AN ELDERLY EDENTULOUS PATIENT: CASE REPORT

ABSTRACT

Giant cell reparative granuloma (GCRG) is a benign reactive intraosseous tumour in the head and neck region, characterized by the presence of multi-nucleated giant cells. It often arises in the first 3 decades of life, with a peak in the second and third decades. However initial presentation of GCRG in elderly patients is rare. The majority of patients are asymptomatic and, in some patients, the lesions are incidentally discovered during radiologic examinations. Presentation with pathologic fractures is rare. The treatment of GCRG is usually surgical, but treatment procedures vary depending on the case. The case reported here describes an elderly edentulous female with a pathologic fracture in the anterior mandibular region. Attention has been focused on the dental findings by computed tomography and surgical treatment of GCRG.

Key Words: Granuloma, Giant Cell; Aged; Fractures, Spontaneous

- Meltem ÖZDEN YÜCE¹
- Murat Cihan SOLMAZ
- Banu ÖZVERİ KOYUNCU
- Gözde TÜRK
- Tayfun GÜNBAY

OLGU SUNUMU

İLERİ YAŞTAKİ TOTAL DİŞSİZ HASTADA MANDİBULADA PATOLOJİK KIRIĞIN EŞLİK ETTİĞİ DEV HÜCRELİ REPARATİF GRANULOM- OLGU SUNUMU

Öz

Dev hücreli reparatif granülom (DHRG) baş-boyun bölgesinde bulunan kemiklerde yerleşim gösteren, çok çekirdekli dev hücrelerin varlığı ile karakterize, benign karakterli bir kemik lezyonudur. Sıklıkla yaşamın ilk 3 dekadında tespit edilmektedir; görülme oranı 2. ve 3.dekatta artış göstermektedir. Bununla birlikte ileri yaştaki hastalarda DHRG'nin ilk defa tespit edilmesi sıra dışı bir durum olarak kabul edilmektedir. Hastaların büyük çoğunluğu asemptomatik olmakla birlikte, birçok hastada lezyon rutin radyografik kontrolde tespit edilmekte, nadiren lezyona patolojik kırık eşlik etmektedir. Tedavisi genellikle cerrahidir ancak tedavi seçenekleri vakaya göre değişkenlik göstermektedir. Bu olgu sunumunda ileri yaşta bulunan dişsiz bir hastada mandibular anterior bölgede patolojik kırığın eşlik ettiği DHRG'nin tomografik bulguları ile tedavisi tanımlanmıştır.

Anahtar Sözcükler: Granüloma; Dev Hücreli; Yaşlı; Kırıklar; Spontan

Correspondance

Meltem ÖZDEN YÜCE
Ege University Faculty of Dentistry,
İZMİR

Phone: 05398261877
e-mail: meltemozdn@hotmail.com

Received: 18/01/2017
Accepted: 22/02/2017

¹ Ege University Faculty of Dentistry,
İZMİR

INTRODUCTION

Giant cell reparative granuloma (GCRG) is a rare solitary bone tumour with unclear etiology and is located in the head and neck region. Although GCRG is a benign, non-odontogenic tumour, it can be locally destructive (1,2).

GCRG accounts for 1%–7% of all benign lesions of the jaw. It is more common in women than in men, and its occurrence is highest in the 2nd and 3rd decades of life. Head and neck involvement of the mandible and maxilla, especially the anterior region of the jaw, is frequently observed (1,3). Etiopathogenesis of these lesions remains unknown, and it is characterized as a trauma or infection-related reactive bone lesion (4).

GCRG is usually a slow-growing lesion, while fast-growing lesions are rare (5,6,7). Despite its innocent histological appearance, GCRG has an aggressive behaviour that clinically mimics a malignant lesion (1). Depending on the location of the lesion, clinical symptoms such as localized swelling, pain, bleeding, nasal obstruction, epistaxis and displacement of teeth may be observed (6,7). A diagnosis is made based on the findings of clinical examinations, radiologic investigations, laboratory tests and histopathological examinations (3).

This report describes the diagnosis and treatment of a rare case of GCRG in an elderly edentulous female with a large lesion and pathologic fracture in the anterior mandibular region. In this report, attention has been focused on the dental findings by computed tomography and surgical treatment for GCRG.

CASE

A 78-year-old edentulous female was diagnosed in our department with a 1-month history of expanding swelling in the anterior region of the mandible and problem with wearing existing removable complete dentures. The patient was edentulous and had been using a complete dentures for more than 20 years. There was no history of trauma in the recent past. She had no systemic complaints, and routine laboratory tests were normal.

Clinical evaluation revealed a mandibular asymmetry of the right mandibular body without any associated cervical lymphadenopathy. Panoramic radiography showed a well-defined radiolucent lesion with insufficient distance between the lesion and the inferior border of the anterior region of the mandible (Figure 1). A cone-beam computed tomography (CBCT) was performed to evaluate the lesion; the lesion was located centrally in the anterior right mandible, with a proximal–distal diameter of 21.0 mm and a buccal–lingual diameter of 13.6 mm (Figure 2). CBCT images showed expansion and perforation of the buccal and lingual cortical plates with a fracture line (Figure 3A,B).

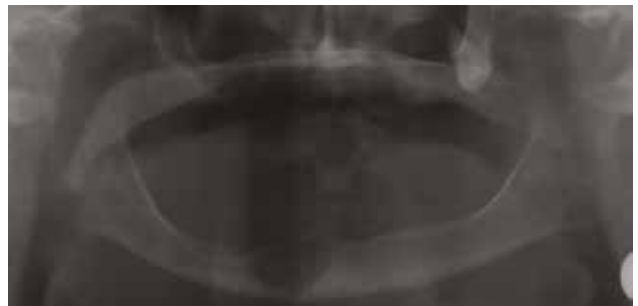

Figure 1: Preoperative radiograph of a well-defined radiolucent lesion which was causing insufficient distance between the lesion and inferior border of the anterior region of mandible.

Based on the clinical and radiological findings, it was presumed that the lesion could be a benign tumour; therefore, surgical treatment was planned and performed under local anaesthesia. The mandible was approached via intra-oral access, and the lesion was completely excised (Figure 4). Because of the presence of the fracture line, an osteosynthesis plate was placed on the buccal cortical bone in the anterior mandibular region. A pre-modelled titanium 2.0-mm miniplate (Synthes GmbH, Switzerland) with 14 holes was adapted to the buccal cortical bone. After the adaptation of the plate, 9 holes were drilled into the bone, and the miniplate was fixed using 10-mm screws. During the adaptation of the plate, attention was paid to the protection of the mental nerve (Figure 5A, B). The surgically removed enucleated material



was sent for histopathologic examination, which confirmed the diagnosis of GCRG (Figure 6). Routine and

special analyses of blood samples were performed to rule out hyperparathyroidism.

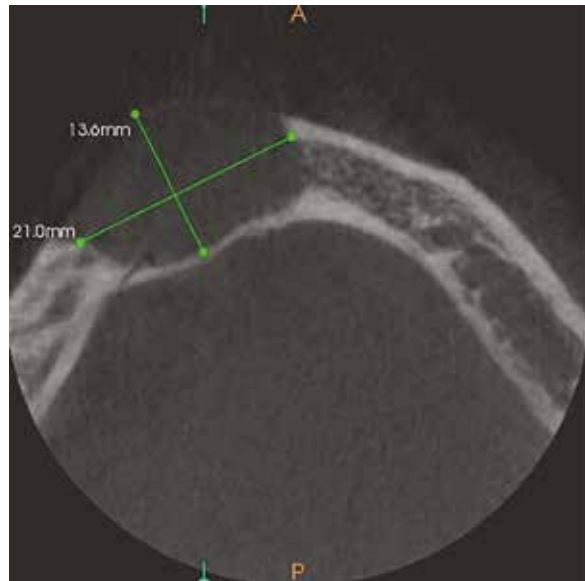
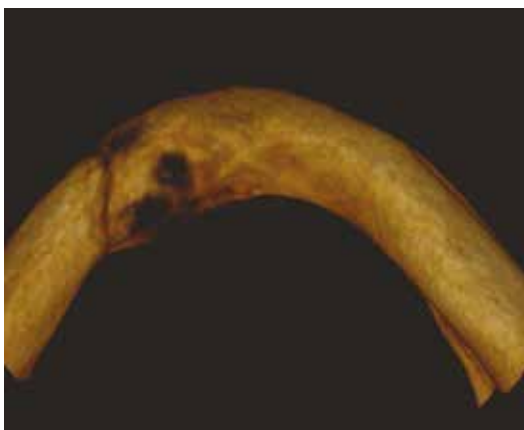


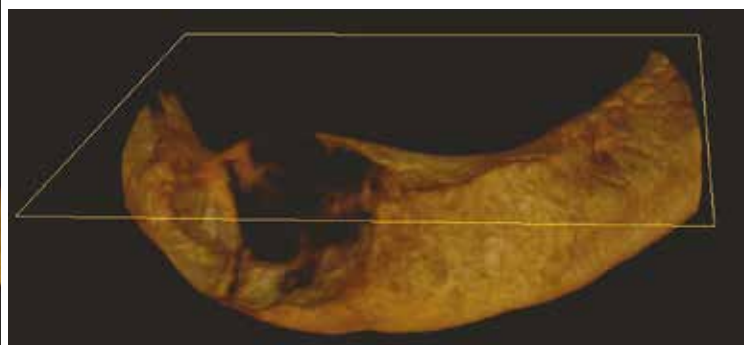
Figure 2: Evaluation of lesion size on cone beam tomography.

The patient was scheduled for frequent routine follow-ups. During the follow-up period, the patient's prosthesis was relined with a soft liner (Viscogel, Dentsply, DeTrey, Germany). Radiologic examination

performed after 2 years showed no signs of recurrence, and the patient's complete set of dentures was re-fabricated (Figure 7,8).



- a -



- b -

Figure 3 A, B: CBCT images showed expansion and perforation of the buccal and lingual cortical plates with a fracture line.

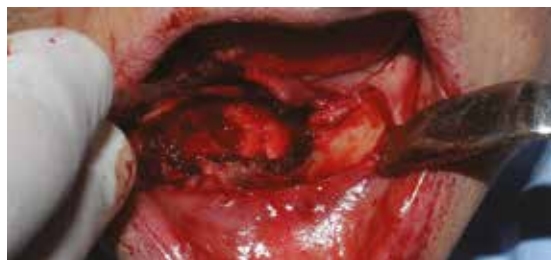
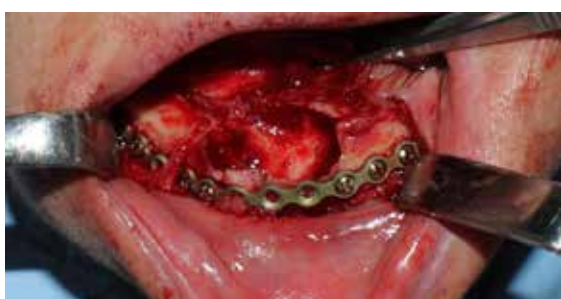
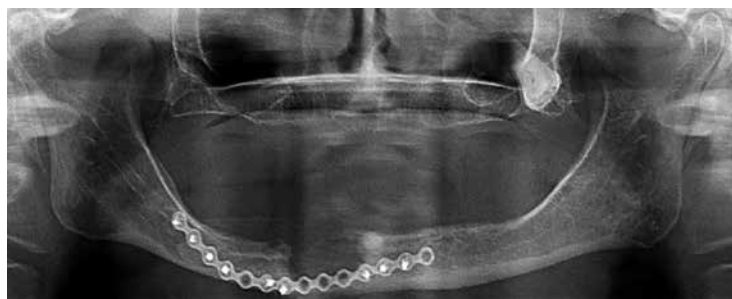Figure 4: The lesion was completely excised under local anesthesia.



- a -



- b -

Figure 5 A, B: A straight titanium miniplate was pre-modeled and adapted to the buccal cortical bone. During the adaptation of the plate attention was paid to the protection of the mental nerve.

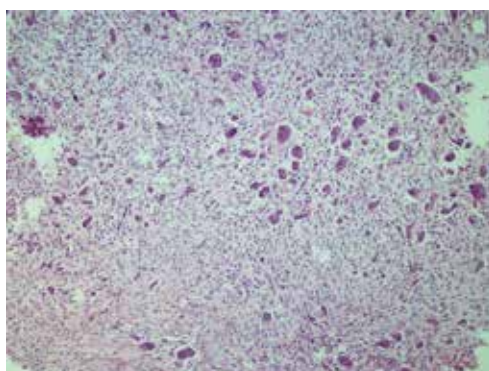


Figure 6: Histopathological view of the lesion.

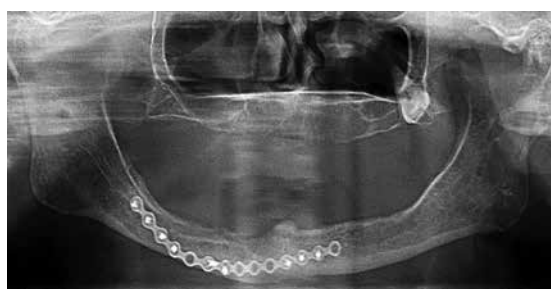


Figure 7: Radiologic examination performed after 2 years showed no signs of recurrence.

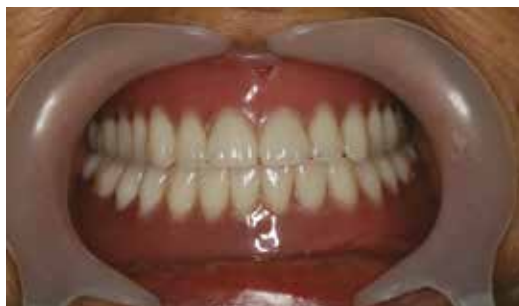

Figure 8: The patient's complete set of dentures was re-fabricated.

DISCUSSION

The term GCRG, an uncommon benign tumour in the head and neck region, was reported by Jaffe in 1953 to describe a reactive intraosseous lesion of the jaw following trauma. Its etiology was described as a trauma-induced bone haemorrhage; however, many patients with GCRG have no history of trauma (4). Local irritation factors such as poor dental restoration, unstable dental prosthesis, dental extraction, plaque and calculus accumulation and food retention appear to play a significant role in the development of GCRG and have been established as causes in some cases (8). Although the biological behaviour of GCRG is still poorly understood, some reports suggest that growth and recurrence of this lesion increases during pregnancy and in the postpartum period, suggesting that hormonal factors play a role in the development of GCRG (3,9). GCRG typically occurs in young adults and is twice as common in females compared with that in males (8). Although GCRG has been observed in patients of all ages, 74% of patients are under the age of 30 years at initial presentation (3). Initial presentation of GCRG is uncommon in patients aged 50 years and above (10). In such cases, in addition to clinical and radiological examination, parathyroid hormone levels and normal serum levels of calcium, phosphorus and alkaline phosphatase must be examined for diagnostic purposes (1,11).

This report presents an unusual case of an elderly, postmenopausal female. In differential diagnosis, this patient was also evaluated for brown tumours, which are particularly common in postmenopausal women

secondary to primary hyperparathyroidism, because of the similarity of histological features.

Although GCRG lesions can be expansive and invasive, generally a majority of patients is asymptomatic. Patients are generally admitted to the clinic with painless swelling on the face or in the oral cavity. GCRG does not involve perineural sheaths; therefore, paraesthesia is not frequently observed in these patients. Other symptoms of GCRG are facial asymmetry, nasal obstruction, displacement or loss of teeth and pathologic fractures (12).

In this case, as compatible with the literature, paraesthesia was not observed. During the intra-oral approach, it was discovered that the patient's mental nerve was superficially located because of the atrophy of the mandible; however, the lesion did not affect it. During the adaptation of the titanium plate, attention was paid to the protection of the mental nerve.

Treatment of GCRG is usually surgery, and the surgical procedures range from simple curettage to block resection (2). It has been reported that approximately 80% of the cases are treated with surgical excision or curettage, and the recurrence rate after surgery range from 10% to 15% (9). Ficarra et al. reported a 72% recurrence rate in patients with aggressive lesions and 3% recurrence rate in patients with non-aggressive lesions (6), whereas Whitaker–Waldron reported a 46.1% recurrence rate in patients with aggressive lesions. Aggressive lesions have a higher recurrence rate because of the incomplete removal of the lesion; to reduce the recurrence rate, curettage and resections must be

meticulous, and re-examination of the lesion for any remaining mass is required after haemostasis (13).

Because of the disadvantages such as the risk of recurrence after surgery, loss of tooth according to the case and loss of tooth germs, alternative methods to surgical treatment such as the use of daily systemic calcitonin and intra-lesional corticosteroid injections have been proposed. In the literature, weekly intra-lesional corticosteroid injections have been reported to have successful results (14,15). Surgical treatment is recommended for painful lesions that grow rapidly, whereas non-surgical treatment is preferred for small, slow-growing lesions (9). Radiotherapy, another treatment method, may cause malignant transformation

in the long-term because of the potential resistance of GCRG to radioactive rays and is therefore not a preferred treatment (16).

In this case, the patient had a history of long-term use of a complete set of dentures; therefore, an unstable dental prosthesis may have acted as an irritating factor and played a role in GCRG development. Additionally, because of the pathologic fracture in the mandible, total curettage of the lesion was chosen instead of a long-term calcitonin or steroid treatment. The lesion did not recur within the 2-years follow-up period, and the complete set of dentures was re-fabricated to avoid soft tissue trauma and possible development of a new GCRG lesion.

REFERENCES

1. De Corso E, Politi M, Marchese MR, Pirroni T, Ricci R, Paludetti G. Advanced giant cell reparative granuloma of the mandible: radiological features and surgical treatment. *Acta Otorhinolaryngol Ital* 2006;26(3):168-72. (PMID: 17063987).
2. Bataineh AB, Al-Khateeb T, Rawashdeh MA. The surgical treatment of central giant cell granuloma of the mandible. *J Oral Maxillofac Surg* 2002;60(7):756-61. (PMID:12089688).
3. Mittal S, Naseem I, Akhtar K, Ahmad I, Khalid M. Multifocal giant cell reparative granuloma involving maxilla and mandible: a rare entity. *Ann Saudi Med* 2015;35(4):321-3. (PMID:26497714).
4. Jaffe HL. Giant-cell reparative granuloma, traumatic bone cyst, and fibrous (fibro-oseous) dysplasia of the jawbones. *Oral Surg Oral Med Oral Pathol* 1953;6(1):159-75. (PMID:13026160).
5. Cassatly MG, Greenberg AM, Kopp WK. Bilateral giant cell granuloma of the mandible: report of case. *J Am Dent Assoc* 1988;117(6):731-3. (PMID:3198881).
6. Ficarra G, Kaban LB, Hansen LS. Central giant cell lesions of the mandible and maxilla: a clinicopathologic and cytometric study. *Oral Surg Oral Med Oral Pathol* 1987;64(1):44-9. (PMID:3475657).
7. Ciorba A, Altissimi G, Giansanti M. Giant cell granuloma of the maxilla: case report. *Otorhinolaryngol Ital* 2004;24(1):26-9. (PMID:15270430).
8. Etoz OA, Demirbas AE, Bulbul M, Akay E. The peripheral giant cell granuloma in edentulous patients: report of three unique cases. *Eur J Dent* 2010;4(3):329-33. (PMID:20613923).
9. Orhan E, Erol S, Deren O, Sevin A, Ekici O, Erdogan B. Idiopathic bilateral central giant cell reparative granuloma of jaws: a case report and literature review. *Int J Pediatr Otorhinolaryngol* 2010;74(5):547-52. (PMID:20219254).
10. Eisenbud L, Stern M, Rothberg M, Sachs SA. Central giant cell granuloma of the jaws: experiences in the management of thirty-seven cases. *J Oral Maxillofac Surg* 1988 May;46(5):376-84. (PMID:3163371).
11. Masson EA, MacFarlane IA, Bodmer CW, Vaughan ED. Parathyroid carcinoma presenting with a brown tumour of the mandible in a young man. *Br J Oral Maxillofac Surg* 1993;31(2):117-9. (PMID:8471574).
12. Ustündağ E, Iseri M, Keskin G, Müezzinoğlu B. Central giant cell granuloma. *Int J Pediatr Otorhinolaryngol* 2002;65(2):143-6. (PMID:12176185).
13. Whitaker SB, Waldron CA. Central giant cell lesions of the jaws. A clinical, radiologic, and histopathologic study. *Oral Surg Oral Med Oral Pathol* 1993;75(2):199-208. (PMID:8426719).
14. Khafif A, Krempel G, Medina JE. Treatment of giant cell granuloma of the maxilla with intralesional injection of steroids. *Head Neck* 2000;22(8):822-5. (PMID: 11084644).
15. Harris M. Central giant cell granulomas of the jaws regress with calcitonin therapy. *Br J Oral Maxillofac Surg* 1993;31(2):89-94. (PMID:8471587).
16. Smith PG, Marrogi AJ, Delfino JJ. Multifocal central giant cell lesions of the maxillofacial skeleton: a case report. *J Oral Maxillofac Surg* 1990;48(3):300-5. (PMID:2303939).