



Turkish Journal of Geriatrics  
2025; 28(1):39–46

DOI: 10.29400/tjgeri.2025.420

Meltem ÖZDEN YÜCE<sup>1</sup>  
 Emine ADALI<sup>2</sup>  
 Gözde IŞIK<sup>1</sup>  
 Mehmet Cemal AKAY<sup>1</sup>  
 Ali VERAL<sup>3</sup>  
 Muharrem Ergün DUDAK<sup>1</sup>

<sup>1</sup>Ege University School of Dentistry, Oral and Maxillofacial Surgery, Izmir, Turkey

<sup>2</sup>Private Clinic, Oral and Maxillofacial Surgery, Istanbul, Turkey

<sup>3</sup>Ege University, Medical Pathology, Izmir, Turkey

#### Correspondence

Meltem ÖZDEN YÜCE  
Phone : +905398261877  
e-mail : meltemozdn@hotmail.com

Received : Dec 12, 2024  
Accepted: Feb 15, 2025

## ORIGINAL ARTICLE

# ANALYSIS OF ORAL AND MAXILLOFACIAL PATHOLOGIES AMONG A SAMPLE OF THE ELDERLY PATIENTS FROM A SINGLE INSTITUTE IN TURKEY: A RETROSPECTIVE STUDY

## ABSTRACT

**Introduction:** The global elderly population is increasing and becoming more susceptible to oral and systemic diseases. Therefore, comprehensive clinical and histopathological examinations of the oral and maxillofacial area to assess the oral health of this population are crucial. This study aimed to increase the knowledge base regarding the prevalence of biopsied oral and maxillofacial lesions among a sample of the elderly Turkish population ( $\geq 65$  years of age).

**Materials and Method:** The clinical records of geriatric patients  $\geq 65$  years of age, who underwent biopsy for a pathological formation(s) in the oral region between January 2017 and January 2020 at Ege University School of Dentistry, Department of Oral and Maxillofacial Surgery (Izmir, Türkiye), were reviewed. Clinical follow-up data including demographic information, anatomical localization of the pathological mass, preliminary diagnosis, and biopsy results were evaluated. In order to ascertain the relationship between lesion formation and the independent variables, univariate analysis was employed.

**Results:** Data were collected from 353 of 400 patients over a three-year period. There was a high prevalence of odontogenic lesions (42.5%), and pathological diagnosis revealed an increased number of cases (43.1%). Pathological lesions were reported mostly in the posterior mandible (33.4%), followed by the anterior maxilla (21%), anterior mandible (13.3%), and posterior maxilla (7.1%).

**Conclusion:** These findings are in accordance with those of previous studies based on histopathological data, emphasizing their importance in guiding public health policies for this patient population.

**Keywords:** Biopsy; Pathology, Oral; Epidemiology; Geriatrics.

#### Cite this article as:

Özden Yüce M, Adalı E, Işık G, Akay MC, Veral A, Dudak ME. Analysis of Oral and Maxillofacial Pathologies among a Sample of the Elderly Patients from a Single Institute in Turkey: A Retrospective Study. Turkish Journal of Geriatrics 2025; 28(1):39–46. doi: 10.29400/tjgeri.2025.420

## INTRODUCTION

The oral and maxillofacial regions are susceptible to a wide range of lesions encompassing both inflammatory processes and malignant neoplasms. These lesions exhibit various manifestations including pain, paresthesia, swelling, tooth loss, root resorption, and facial deformities. Such occurrences can manifest at any stage of a patient's lifespan, potentially leading to significant aesthetic and functional loss. Therefore, it is crucial to implement a comprehensive treatment plan and histopathological diagnosis to ensure optimal outcomes (1,2).

Over the last decade, the proportion of people aged  $\geq 60$  years has increased at a faster rate globally than any other age group. Despite the prevalence of oral and dental diseases in this patient population, there have been few efforts to address their treatment needs. Oral health has received less attention than systemic health in the geriatric patients  $\geq 65$  years of age, and patients in this demographic who require assistance with the numerous activities of daily living may be less inclined to prioritize oral health (3,4).

The number of individuals  $> 65$  years of age was 524 million in 2010; however, this number is projected to exceed 1 billion by 2050 (5). In response to the ageing population and increasing interest in the oral health of older adults, a significant number of scientific studies have been conducted, many of which have analysed clinical data (6). A number of studies have demonstrated that older people are about 10 times more likely to have potentially malignant oral lesions than younger people (6,7,8). However, geriatric patients  $\geq 65$  years of age have a significantly higher incidence of reactionary and inflammatory lesions, malignant epithelial neoplasms, premalignant lesions, autoimmune diseases, and salivary gland tumors than younger individuals (7).

Although lesions in the oral, dental, maxillofacial, and facial regions are similar worldwide, their incidences may vary regionally. Based on this

information, a statistical study conducted in the  $\geq 65$  years of age population of our region will help dentists make preliminary diagnoses of the lesions they encounter to inform treatment planning and timing.

## MATERIALS AND METHOD

The study protocol was approved by the Ege University Clinical Research Ethics Committee (date, approval number, 20-9T/71). In consideration of the retrospective nature of this study and the utilisation of anonymised patient data, the necessity for informed consent was not required. The study was in accordance with the Declaration of Helsinki.

In this study, biopsy records of oral maxillofacial lesions obtained from geriatric patients  $\geq 65$  years of age and histopathologically diagnosed between January 2017 and July 2022 at Ege University Faculty of Dentistry (Bornova, Türkiye) were evaluated.

A retrospective examination of medical records was performed on patients who had undergone biopsy for any pathological mass in the oral or maxillofacial region(s), whose clinical notes were complete and available in the file, and who had received a pathological diagnosis pertaining to the maxillofacial region. Patient data were transferred to a spreadsheet database (Excel, Microsoft Corporation, Redmond, WA, USA). Patients with insufficient clinical data and those for whom pathological results were not available in the system were excluded.

The dataset comprised information regarding age, sex, preliminary pathological diagnosis, final pathological diagnosis, site of the pathological mass, and systemic disease. Biopsy sites included the anterior and posterior maxillae, anterior and posterior mandibles, and other soft tissues (tongue, cheek, and palate). The biopsied lesions were evaluated according to 5 main categories: odontogenic cysts; reactive and inflammatory lesions; osteonecrosis; malignant soft and hard



tissue tumors; and others. Consideration was given to lesions frequently observed in the geriatric patient population.

### Statistical analysis

The statistical analysis was performed using the 20.0 Statistical Package For The Social Sciences (SPSS) version (IBM Corporation, Armonk, NY, USA). Frequency values were calculated for the distribution of variables related to the descriptive characteristics, disease information, and pathological conditions of the patients in the study, and are expressed as number of cases (n) and percentage (%). The distribution of the final histopathological results according to region is presented in the cross-tabulations. Furthermore, the McNemar–Bowker test was used to assess the agreement between the preoperative diagnoses of the patients and the distribution of the final histopathological results. Statistical significance level was set at  $p < 0.05$ .

## RESULTS

Data from 400 patients were retrospectively reviewed; however, 22 with inadequate clinical notes and 14 without histopathological results were excluded. Among the remaining 353 patients, 165 (46.7%) were male and 188 (53.3%) were female, with a mean ( $\pm$  SD) age of  $71.15 \pm 5.21$  years (range 65 to 89 years) (Table 1).

The most commonly diagnosed pathological masses were odontogenic cysts (43.1%), followed by reactive and inflammatory lesions (32.0%). The most common biopsy site was the posterior mandibular region (33.4%) and the least common was the posterior maxillary region (7.1%). Of the patients included, 60.9% exhibited evidence of systemic disease, the most prevalent of which was hypertension, observed in 120 (55.8%) (Table 1).

Preliminary diagnosis indicated that odontogenic cysts accounted for 150 (42.5%) cases. However, pathological diagnosis revealed that the number of

**Table 1.** Description of patients regarding to age, gender, medical conditions, and diagnosis

Variables	Overall (n=353)
<b>Gender n (%)</b>	
Male	165 (46.7)
Female	188 (53.3)
<b>Age, mean</b>	$71.15 \pm 5.21$ (65.0-89.0)
<b>Preliminary diagnosis n (%)</b>	
Odontogenic cysts	150 (42.5)
Reactive and inflammatory lesions	118 (33.4)
Osteonecrosis	51 (14.5)
Malignant hard-and soft-tissue tumors	29 (8.2)
Other	5 (1.4)
<b>Pathological diagnosis n (%)</b>	
Odontogenic cysts	152 (43.1)
Reactive and inflammatory lesions	113 (32.0)
Osteonecrosis	51 (14.5)
Malignant hard-and soft-tissue tumors	34 (9.6)
Other	3 (0.8)
<b>Region n (%)</b>	
Anterior maxilla	74 (21.0)
Posterior maxilla	25 (7.1)
Anterior mandible	47 (13.3)
Posterior mandible	118 (33.4)
Other (Tongue, Buccal, Lip)	89 (25.2)
<b>Medical Conditions n (%)</b>	
Diabetes mellitus	67 (31.2)
Hypertension	120 (55.8)
Cardiovascular diseases	34 (15.8)
Onkology	54 (25.1)
Other	30 (14.0)

cases increased to 152 (43.1%). Similarly, preliminary diagnosis indicated that 118 (33.4%) patients were affected by reactive and inflammatory lesions. However, pathological diagnosis indicated that the

number of cases decreased to 113 (32.0%). There was no discrepancy in data pertaining to osteonecrosis when the preliminary and pathological diagnoses were evaluated. Malignant soft- and hard-tissue tumors constituted 29 (8.2%) preliminary diagnoses

and 34 (9.6%) pathological diagnoses (Table 2 and Figure 1).

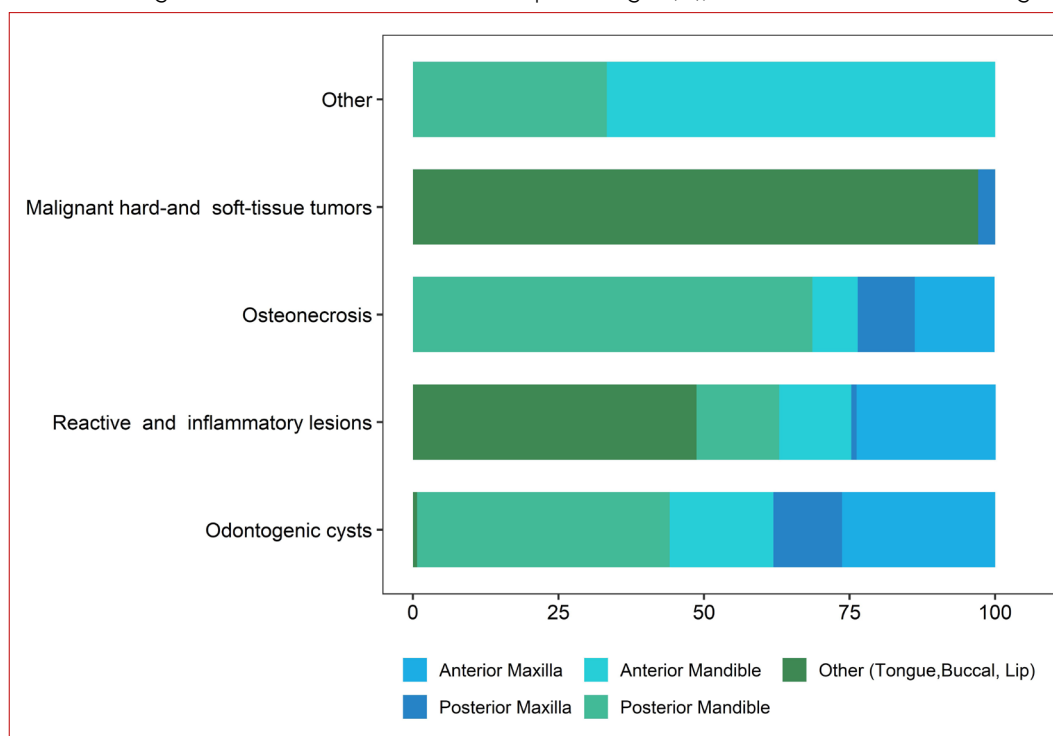
Seventy-four (21%) lesions were located in the maxillary anterior region, 40 (26.3%) of which were odontogenous. Twenty-five (7.1%) were located in

**Table 2.** Distribution of preliminary and pathological diagnoses

	Preliminary Diagnosis (n=353)	Pathological Diagnosis (n=353)	p
	n (%)	n (%)	
Odontogenic cysts	150 (42.5)	152 (43.1)	0.050
Reactive and inflammatory lesions	118 (33.4)	113 (32.0)	
Osteonecrosis	51 (14.5)	51 (14.5)	
Malignant hard-and soft-tissue tumors	29 (8.2)	34 (9.6)	
Other	5 (1.4)	3 (0.8)	

\*<0.05: McNemar-Bowker Test.

**Figure 1.** The bar chart presents the distribution of patient population according to preliminary and pathological diagnoses. Data were summarized with percentages (%), and these columns were categorized in different colors





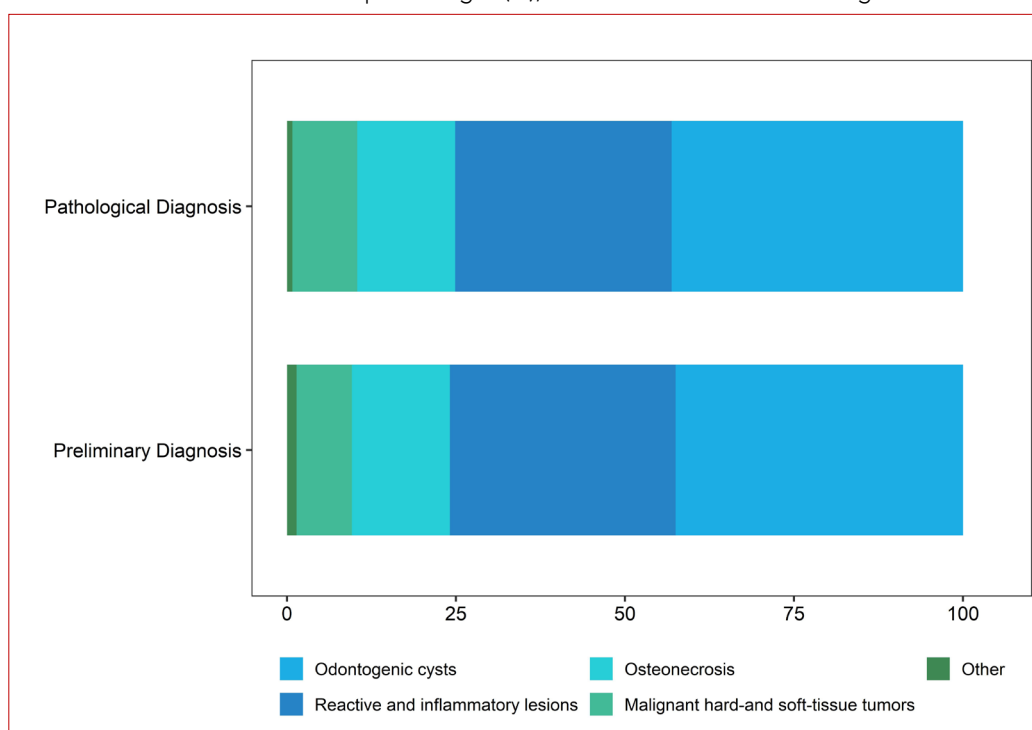
the anterior region of the maxilla, 18 (11.8%) of which were odontogenic cysts. A total of 47 (13.3%) lesions were located in the anterior mandibular region, of which 27 (17.8%) were odontogenic cysts. In the posterior mandibular region, 118 (33.4%) lesions were

identified, of which 66 (43.4%) were odontogenic cysts. A total of 89 (25.2%) lesions were located in other regions, including the tongue, cheeks, and lips. Of these patients, 55 (48.7%) had reactive and inflammatory lesions (Table 3 and Figure 2).

**Table 3.** Distribution of pathological diagnosis according to region

Region	Pathological Diagnosis					Total
	Odontogenic Cysts (n=152)	Reactive and inflammatory lesions (n=113)	Osteonecrosis (n=51)	Malignant hard-and soft-tissue tumors (n=34)	Other (n=3)	
	n (%)	n (%)	n (%)	n (%)	n (%)	
Anterior Maxilla	40 (26.3)	27 (23.9)	7 (13.7)	0 (0)	0 (0)	74 (21)
Posterior Maxilla	18 (11.8)	1 (0.9)	5 (9.8)	1 (2.9)	0 (0)	25 (7.1)
Anterior Mandible	27 (17.8)	14 (12.4)	4 (7.8)	0 (0)	2 (66.7)	47 (13.3)
Posterior Mandible	66 (43.4)	16 (14.2)	35 (68.6)	0 (0)	1 (33.3)	118 (33.4)
Other (Tongue, Buccal, Lip)	1 (0.7)	55 (48.7)	0 (0)	33 (97.1)	0 (0)	89 (25.2)

**Figure 2.** The bar chart presents the distribution of patient population based on pathological diagnosis in region. Data were summarized with percentages (%), and these columns were categorized in different colors.



## DISCUSSION

Numerous studies have investigated the incidence and prevalence of oral lesions in geriatric patients  $\geq 65$  years of age. However, many were based solely on clinical diagnoses, which can result in inaccurate findings and inappropriate treatment strategies. In many cases, a definitive diagnosis necessitates a histopathological analysis, which is regarded as the gold standard for the identification of numerous pathological conditions. It is thus important to stress that the discordance between clinical and histopathological diagnoses can lead to treatment errors and adverse patient outcomes. Consequently, healthcare professionals should implement the practice of sending all biopsied specimens for histopathological analysis to facilitate a more precise and comprehensive assessment of a patient's condition (4,8).

It is vital for dental professionals to be aware of the most prevalent conditions affecting the geriatric patients  $\geq 65$  years of age in their daily clinical practice. This enables them to diagnose simple diseases, conditions, and more complex conditions. Therefore, it is important to conduct epidemiological studies to determine the frequency and predominant features of oromaxillofacial lesions (9).

Results of the present study revealed a slightly higher prevalence of oral maxillofacial lesions in females versus males, which is consistent with findings reported in other studies (10,11). Nevertheless, some studies have identified a higher prevalence of oral lesions among males, which can be affected by several factors, including demographic, geographical, social, and cultural variables. For example, a higher prevalence of oral lesions has been reported in China, where males constitute  $> 50\%$  of the population (12). Furthermore, inequalities in access to and use of health services between males and females may affect the identification and diagnosis of these lesions (4).

The prevalence of oral lesions is reportedly higher in the geriatric patients  $\geq 65$  years of age versus the young(er) population (13, 14). It has been reported that the epithelium of the oral cavity becomes thinner with age. Furthermore, it is reported that, the oral mucosa is rendered more vulnerable to harmful substances and more susceptible to external carcinogens due to reduced immunological reactivity, impaired DNA repairing capacity and impaired carcinogenic metabolism. However, age alone is not the only contributor; others, including systemic/dental conditions, medications used, poor nutritional status and poor oral hygiene may also affect the development of oral lesions (13, 14, 15, 16). Although both clinical- and biopsy-based studies have demonstrated that the reactive/inflammatory category is the most prevalent diagnostic category in this age group, the results of this study are consistent with those of biopsy-based studies. Reactive and inflammatory soft tissue lesions are the most commonly diagnosed pathological masses in soft tissue regions such as the tongue, cheek, and lips.

Oral lesions can be observed in various anatomical regions of the body. The tongue and labial/buccal mucosa are the most commonly affected soft-tissue sites, and intraosseous lesions mostly occur in the mandible. These findings were consistent with those of previous studies. The tongue and labial/buccal mucosa are the most common anatomical sites because the 5 most commonly diagnosed lesions (fibrous/fibroepithelial hyperplasia, squamous cell carcinoma, epithelial dysplasia, hyperkeratosis/acanthosis, and lichen planus) are primarily observed at these sites (14,16). The distribution of the data in the present study was similar to that reported in previous studies. Of these, 118 (33.4%) were located in the posterior mandibular region and 66 (43.4%) were odontogenic cysts. The remaining 89 (25.2%) were located in other (tongue, cheek, and lip) regions, 55 (48.7%) of which were reactive and inflammatory lesions.



Several studies have reported that reactive and inflammatory lesions are most common in geriatric patients  $\geq 65$  years of age (4,16,17). The high prevalence of reactive and inflammatory lesions may be related to the increased use of removable prostheses in geriatric patients  $\geq 65$  years of age. The quality of removable prostheses, anatomical factors, and duration of use of removable prostheses may affect the development of these lesions. Therefore, healthcare professionals should provide appropriate instructions to patients using removable prostheses (4,17). It is also important to note that Alzheimer's disease, Parkinson's disease, seizures and other neurodegenerative conditions, which are more prevalent in older individuals, may also influence the formation and development of these lesions (4, 14).

It has been established that clinically reactive and inflammatory lesions should be part of the differential diagnosis of malignant formations, and an accurate diagnosis of malignant diseases is contingent on the use of histopathological methods (16). According to previous studies, the incidence of premalignant and malignant lesions was higher in geriatric patients  $\geq 65$  years of age (16, 18). In our study, 34 patients were diagnosed with malignant soft or hard tissue tumors, 29 of whom were sent for histopathological examination with a preliminary diagnosis of malignancy. Considering the prognosis of malignant formations and morbidity rates in the geriatric population, it is important to subject all biopsy specimens to histopathological examination for definitive diagnosis, even if they are not clinically considered to be malignant.

The limitation of the present study is that it is based on a small sample of the Turkish geriatric patients  $\geq 65$  years of age. Therefore, further studies are needed on this topic to represent the entire population in Turkey.

In conclusion, due to high prevalence of malignancies and potentially malignant diseases, geriatricians and dentists should perform

comprehensive periodic oral examinations for early detection of these lesions to reduce morbidity and mortality and contributing to better patient quality of life. In addition, the moderate agreement observed between the clinical and histopathological diagnoses reinforces the importance of histopathological analysis of all biopsy materials. This practice is essential, considering that clinical evaluations alone may not be sufficient to reach a correct diagnosis.

## REFERENCES

1. Hosgor H, Tokuc B, Kan B, Coskunes FM. Evaluation of biopsies of oral and maxillofacial lesions: a retrospective study. *J Korean Assoc Oral Maxillofac Surg.* 2019;45(6):316-323. doi: 10.5125/jkaoms.2019.45.6.316
2. Bataineh AB, Rawashdeh MA, Al Qudah MA. The prevalence of inflammatory and developmental odontogenic cysts in a Jordanian population: a clinicopathologic study. *Quintessence Int.* 2004;35(10):815-819. PMID: 15553292
3. Hoeksema AR, Peters LL, Raghoobar GM, Meijer HJA, Vissink A, Visser A. Oral health status and need for oral care of care-dependent indwelling elderly: From admission to death. *Clin Oral Investig.* 2017;21(7):2189-2196. doi: 10.1007/s00784-016-2011-0
4. Silva LP, Leite RB, Sobral APV, et al. Oral and maxillofacial lesions diagnosed in older people of a Brazilian population: a multicentric study. *J Am Geriatr Soc.* 2017;65(7):1586-1590. doi: 10.1111/jgs.14815
5. World Health Organization. World report on ageing and health [e-book] NIH Publication; 2015. [Internet] Available from: <https://www.who.int/publications/i/item/9789241565042>. Accessed: 05.09.2022.
6. Cueto A, Martinez R, Niklander S, et al. Prevalence of oral mucosal lesions in an elderly population in the city of Valparaiso, Chile. *Gerodontology.* 2013;30(3):201-6. doi: 10.1111/j.1741-2358.2012.00663.x
7. Carvalho MV, Iglesias DP, Nascimento GJ, Sobral AP. Epidemiological study of 534 biopsies of oral mucosal lesions in elderly Brazilian patients. *Gerodontology.* 2011;28(2):111-115. doi: 10.1111/j.1741-2358.2010.00370.x

8. Cunha JLS, Cavalcante IL, Rodrigues ABR, et al. A retrospective multicenter study of oral and maxillofacial lesions in older people. *Braz Oral Res.* 2023;37:e098. doi: 10.1590/1807-3107bor-2023.vol37.0098
9. Almeida C, Freitas F, Francisco H, Marques JA, Caramês J. Oral biopsies in a Portuguese population: A 20-year clinicopathological study in a university clinic. *J Clin Exp Dent.* 2022 ;14(12):e1024-e1031. doi: 10.4317/jced.59688
10. Alhindi N, Sindi A, Binmadi N, Elias W. A retrospective study of oral and maxillofacial pathology lesions diagnosed at the Faculty of Dentistry, King Abdulaziz University. *Clin Cosmet Investig Dent.* 2019;11:45-52. doi: 10.2147/CCIDE.S190092
11. Monteiro L, Albuquerque R, Paiva A, de la Peña-Moral J, Amaral J, Lopes C. A comparative analysis of oral and maxillofacial pathology over a 16-year period, in the north of Portugal. *Int Dent J.* 2017;67(1):38-45. doi: 10.1111/idj.12258
12. Lin HC, Corbet EF, Lo EC. Oral mucosal lesions in adult Chinese. *J Dent Res.* 2001;80(5):1486-1490. doi: 10.1177/00220345010800052001
13. Mumcu G, Cimilli H, Sur H, Hayran O, Atalay T. Prevalence and distribution of oral lesions: a cross-sectional study in Turkey. *Oral Dis.* 2005;11(2):81-87. doi: 10.1111/j.1601-0825.2004.01062.x
14. Bozdemir E, Görmez Ö, Yilmaztürk S. S. Clinical and Radiographic Findings in Older and Non-older Patients Applying to the Faculty of Dentistry. *Eur J Geriatric Gerontol.* 2024; 6(2), 131-138. doi: 10.4274/ejgg.galenos.2024.2023-7-2
15. Reichart PA. Oral mucosal lesions in a representative cross-sectional study of aging Germans. *Community Dent Oral Epidemiol.* 2000;28(5):390-398. doi: 10.1034/j.1600-0528.2000.028005390.x
16. Dhanuthai K, Rojanawatsirivej S, Somkotra T, et al. Geriatric oral lesions: a multicentric study. *Geriatr Gerontol Int.* 2016;16(2):237-243. doi: 10.1111/ggi.12458
17. Fonseca MF, Kato CO, Pereira MC, et al. Oral and maxillofacial lesions in older individuals and associated factors: a retrospective analysis of cases retrieved in two different services. *J Clin Exp Dent.* 2019;11(10):e921-e929. doi: 10.4317/jced.56194
18. Korkmaz MO, Dikicier BS, İlhan N, Güven M. The correlation of oral mucosa lesions with dermatological preliminary diagnosis and epidemiological properties. *ENT Updates,* 2020;10(3), 409-417. doi:10.32448.entupdates.825640