

Barçın ÖZCEM<sup>1</sup>  
Feyza YAYCI<sup>2</sup>  
Serpil DEREN<sup>2</sup>

İletişim (Correspondance)

Barçın ÖZCEM  
Yakın Doğu Üniversitesi Tıp Fakültesi  
Kalp ve Damar Cerrahisi Anabilim Dalı  
LEFKOŞA, KUZEY KIBRIS TC

Tlf: 0392 675 10 00  
e-posta: drbarcinozcem@gmail.com

Geliş Tarihi: 27/08/2013  
(Received)

Kabul Tarihi: 26/10/2013  
(Accepted)

<sup>1</sup> Yakın Doğu Üniversitesi Tıp Fakültesi  
Kalp ve Damar Cerrahisi Anabilim Dalı  
LEFKOŞA, KUZEY KIBRIS TC  
<sup>2</sup> Yakın Doğu Üniversitesi Tıp Fakültesi  
Anestezi ve Reanimasyon Anabilim Dalı  
LEFKOŞA, KUZEY KIBRIS TC



CASE REPORT

## PROPOFOL-RELATED INFUSION SYNDROME IN A GERIATRIC PATIENT FOLLOWING THE USE OF PROPOFOL IN LOW DOSES AND SHORT DURATION, DURING AND AFTER CARDIAC SURGERY: A CASE REPORT

### ABSTRACT

Propofol, is a potent short-acting intravenous sedative-hypnotic agent used for induction and maintenance of general anesthesia and to provide continuous sedation in the intensive care unit. Propofol-related infusion syndrome is a rare yet often fatal syndrome associated with the continuous infusion of propofol. It is characterized by severe metabolic acidosis, cardiac failure, bradycardia, myoglobinuria and renal failure. Hereby we present a case of propofol-related infusion syndrome which developed in 74 years of age patient, following coronary artery by-pass grafting and aortic valve replacement surgery in the early postoperative period. Low dose propofol was used both intraoperatively and in the intensive care unit postoperatively. The patient developed severe lactic acidosis, oliguria and bradycardia requiring cardiac pacing in the sixth hour postoperatively. Lactic acidosis and clinical condition improved promptly within a few hours, following the discontinuation of propofol infusion.

**Key Words:** Propofol; Acidosis, lactic; Cardiac Surgical Procedures; Aged.



### OLGU SUNUMU

## GERİATRİK HASTADA AÇIK KALP AMELİYATI SIRASINDA VE SONRASINDA, PROPOFOLÜN DÜŞÜK İNFÜZYON DOZUNDA VERİLMESİNE RAĞMEN GELİŞEN PROPOFOL İNFÜZYON SENDROMU

### Öz

Propofol, genel anestezi indüksiyonunda ve idamesinde, ayrıca yoğun bakımda sedasyon amacıyla kullanılan, kısa etkili potent bir hipnotik-sedatif ajandır. Propofol infüzyon sendromu, propofolün devamlı infüzyonuna bağlı gelişebilen, ender, ancak sıklıkla ölümlü sonuçlanabilen bir durumdur. Ağır metabolik asidoz, kalp yetersizliği, bradikardi, miyoglobinüri ve böbrek yetersizliği ile karakterizedir. Bu makalede, koroner arter bypass greftleme ve aort kapağı replasmanı uygulanan 74 yaşında bir hastada postoperative erken dönemde gelişen propofol infüzyon sendromu bildirilmektedir. Hastaya anestezi sırasında ve postoperatif yoğun bakım sedasyonu sırasında düşük doz propofol uygulandı. Hastada, postoperative altıncı saatte ağır laktik asidoz, oligüri ve pacemaker gerektiren bradikardi gelişti. Propofol kesildikten sonra laktik asidoz ve hastanın genel durumunda bir kaç saat içinde hızlı bir düzelme kaydedildi.

**Anahtar Sözcükler:** Propofol İnfüzyon Sendromu; Laktik Asidoz; Kardiyak Cerrahi; Yaşlı.



## INTRODUCTION

Propofol, is a commonly used intravenous sedative-hypnotic agent utilized for anesthetic induction and maintenance, and sedation of the mechanically ventilated patients. Propofol-related infusion syndrome (PRIS) is a serious side effect of propofol infusion, characterized by severe metabolic acidosis, cardiac failure, bradycardia, hyperpyrexia, rhabdomyolysis, myoglobinuria and renal failure (1). PRIS is classically known to occur in pediatric patients, and with propofol doses of higher than 4 mg/kg/hr and duration of infusion more than 48 hours (2). We present a case of PRIS in a geriatric patient (74y) who underwent coronary artery by-pass grafting (CABG) and aortic valve replacement (AVR) surgery. Propofol was used in doses smaller than usual, both in the induction and the maintenance of anesthesia, and in the early postoperative period in intensive care unit (ICU). Severe metabolic acidosis, oliguria and bradycardia requiring cardiac pacing developed in the 6<sup>th</sup> hour postoperatively. The clinical condition was attributed to PRIS, and cessation of propofol infusion led to recovery of the findings dramatically. Presenting that case, we wanted to emphasize that propofol infusion even in small doses could result in PRIS in geriatric patients.

## CASE

A 73 year-old male with severe aortic regurgitation and coronary artery disease was scheduled for CABG and

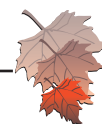
AVR surgery. The patient was under antihypertensive and anti-lipidemic therapy and his baseline arterial blood pressure was 130/70mmHg, heart rate 66/min and left ventricular ejection fraction was 60%. The induction of anesthesia was performed with midazolam 4mg, fentanyl 200mcg, propofol 50mg and rocuronium 50mg. The maintenance of anesthesia was implemented with sevoflurane inhalation, fentanyl infusion and incremental doses of propofol not exceeding a total dose of 250 mg. The course of anesthesia was uneventful except for a rise in lactic acid level up to 24 mg/dl with a compensated metabolic acidosis with negative base excess levels of 3-5 during the cardiopulmonary by-pass period. Following the removal of the x-clamp, infusion of norepinephrine and epinephrine in doses of 0.02 mcg/kg/min was initiated. In the ICU an infusion of propofol 2mg/kg/h was given during the mechanical ventilation. In the 1<sup>st</sup> hour of ICU stay, the patient became hypertensive and the propofol infusion was increased to a dose of 2.5 mg/kg/h while the vasopressor support was terminated. By the 6<sup>th</sup> hour of the ICU stay, the patient developed severe bradycardia (35/min) requiring cardiac pacing eventually. The blood gases revealed metabolic acidosis with gradually increasing lactate levels accompanied by hyperkalemia and oliguria (Table 1). The rate of intravenous fluid infusion was increased with the guidance of central venous pressure and vasopressor therapy with epinephrine (0.02mcg/kg/min) and norepinephrine (0.02 mcg/kg/min) was initiated to restore tissue perfusion. Laboratory tests revealed a significant elevation in liver enzymes and triglyceride, creatine kinase, urea and creatinine

**Table 1—** Postoperative Blood Pressure, Heart Rate, Blood Gases, Lactate and Urinary Output.

	Postop 0. hrs	Postop 3. hrs	Postop 6. hrs	Postop 7. hrs	Postop 8. hrs	Postop 9. hrs	Postop 10. hrs	Postop 11. hrs	Postop 12. hrs	Postop 15. hrs
Blood pressure (mmHg)	115/85	130/65	95/65	127/75	105/70	90/60	123/83	135/85	142/85	125/70
Heart rate	85/min	82/min	35/min	80/min	80/min	80/min	80/min	80/min	93/min	78/min
			<b>a</b>	<b>a</b>	<b>a</b>	<b>a</b>	<b>a</b>	<b>a</b>		
pH	7.45	7.42	7.25	7.2	7.18	7.22	7.34	7.36	7.4	7.45
HCO <sub>3</sub> <sup>-</sup> (mmol/L)	28	26.2	18.5	15	16	16.5	23	23.5	25	28
Lactate (mg/dL)	30	35	40	107	134	144	80	15	10	12
Base excess (mmol/L)	4	1.8	-8.2	-12	-11.2	-12	-3.5	-3	1	2.5
Sodium(Na)(mmol/L)	134	138	135	142	145	148	146	145	145	142
potassium(K)(mmol/L)	3.94	4.23	4.5	5.15	5.8	6.2	5.2	4.8	4.9	4.5
Urine output (mL/hr)	160	130	25	30	25	35	80	100	120	140

**a** cardiac pacing was calibrated at 80/dk.

Postop: Postoperative.



**Table 2—** Preoperative and Postoperative 15 hrs Laboratory Test Results.

	Preoperative	Postoperative 15th hour	Normal range
Urea mg/dl	45	80	18-55
Creatinine mg/dl	1.2	1.69	0.70-1.20
Creatine kinase U/L	80	2132	20-200
Myoglobin ng/ml	-	1120	19-51
Creatine kinase-MB U/L	12	124	0-25
Troponin ng/ml	0.01	0.07	0.000-0.014
SGOT U/L	15	120	0-40
SGPT U/L	16	24	0-40
Triglyceride mg/dl	140	280	0-150

levels (Table 2). In the 8<sup>th</sup> postoperative hour the patient developed diffuse skin rash following antibiotherapy, which was attributed to an allergic reaction and treated with 125 mg methylprednisolone causing a deterioration in lactic metabolic acidosis. Exclusion of potential etiologic factors led us to the diagnosis of PRIS in the 10<sup>th</sup> postoperative hour. We discontinued propofol infusion resulting in a prompt and considerable improvement in the lactic acidosis, bradycardia and oliguria. The patient was discharged from the ICU on the postoperative 5<sup>th</sup> day with full recovery.

## DISCUSSION

Propofol-related infusion syndrome was first defined by Bray in 1998 as a sudden onset of marked bradycardia resistant to treatment, with progression to asystole plus one of the following: hyperlipidemia, fatty infiltration of the liver, severe metabolic acidosis, or muscle involvement with evidence of rhabdomyolysis or myoglobinuria. There is both clinical and experimental evidence to suggest that propofol can trigger dysfunction of the mitochondrial respiratory chain, leading to depletion of ATP production and cellular hypoxia in tissues such as the heart and muscle (3). Fat overload associated with propofol infusion may contribute to increased plasma fatty acids which may lead to arrhythmias (4). This syndrome was initially recognized only in children, but has become increasingly recognized in adults (5). Postulated risk factors for PRIS include use of a high propofol dose (> 83 mcg/kg/min), a duration of therapy of > 48 hours, and concomitant vasopressor therapy. However, it needs to be stressed that PRIS can occur soon after the initiation of propofol therapy and even also at rather low doses (6). In our case, infusion dose of

propofol was 2-2.5mg/kg/h (corresponding to a total dose of 40mcg/kg/min), and duration of the infusion was approximately 9 hours. Our case revealed that PRIS could also be seen with the use of propofol even in low doses and short duration in geriatric patients undergoing cardiac surgery. Presence of triggering factors such as catecholamine infusion or corticosteroids were also reported to contribute to the development of PRIS (2). There is evidence suggesting an association between propofol infusion and catecholamine response as a cause of PRIS (7). Besides, steroids are commonly cited as a cause of muscle damage which presents as rhabdomyolysis in the setting of critical illness (8). In our case, the use of catecholamine for the management of metabolic acidosis and corticosteroids for the skin rash, led to further deterioration in lactic acidosis. Our case also presented an increase in CK, CK-MB, troponine, myoglobine, urea and creatinine values postoperatively, which was hard to tell whether it was due to PRIS or cardiopulmonary by-pass (9, 3). On the other hand, the lipid profile is known to show no elevation due to cardiopulmonary by-pass itself, but elevated triglyceride levels as in our case, are considered as an early marker in the development of PRIS (10,11). In a study by Fong et al., the mortality rate in PRIS was found to be 30 % and the predictors of mortality were defined. Death was more likely if patients were <or=18 yrs, male, received a vasopressor, or had the following clinical manifestations: cardiac , metabolic acidosis , renal failure, hypotension, rhabdomyolysis, or dyslipidemia (12). Most of those factors existed in our case except for the age, and PRIS did not end up with mortality in our elderly patient after cessation of propofol.

In conclusion, we want to emphasize that, development of PRIS is not limited to prolonged use or high doses of propofol infusion especially in geriatric patients. Concomittant use of catecholamine, hypertriglyceridemia, elevated lactate levels in the absence of tissue hypoxemia and bradycardia may indicate the development of PRIS. Recognizing the early signs and symptoms of PRIS, may have an important impact on the clinical outcomes of patients experiencing this syndrome.

## REFERENCES

- Ahlen K, Buckley CJ, Goodale DB, Pulsford AH. The 'propofol infusion syndrome': the facts, their interpretation and implications for patient care. *Eur J Anaesthesiol* 2006 Dec;23(12):990-8. (PMID:16938158).
- Laquay N, Prieur S, Greff B, Meyer P, Orliaguet G. Propofol infusion syndrome. *Ann Fr Anesth Reanim* 2010 May;29(5):377-86. (PMID:20399595).



3. Fudickar A, Bein B. Propofol infusion syndrome: update of clinical manifestation and pathophysiology. *Minerva Anesthesiol* 2009 May;75(5):339-44. (PMID:19412155).
4. Cremer OL. The propofol infusion syndrome: more puzzling evidence on a complex and poorly characterized disorder. *Crit Care* 2009;13(6):1012. (PMID:20017894).
5. Liolios A, Guérit JM, Scholtes JL, Raftopoulos C, Hantson P. Propofol infusion syndrome associated with short-term large-dose infusion during surgical anesthesia in an adult. *Anesth Analg* 2005 Jun;100(6):1804-6. (PMID:15920217).
6. Roberts RJ, Barletta JF, Fong JJ, et al. Incidence of propofol-related infusion syndrome in critically ill adults: a prospective, multicenter study. *Crit Care* 2009;13(5):R169. (PMID:19874582).
7. Otterspoor LC, Kalkman CJ, Cremer OL. Update on the propofol infusion syndrome in ICU management of patients with head injury. *Curr Opin Anaesthesiol* 2008;21:544-51. (PMID:18784477).
8. Vasile B, Rasulo F, Candiani A, Latronico N. The pathophysiology of propofol infusion syndrome: a simple name for a complex syndrome. *Intensive Care Med* 2003;29(9):1417-25. (PMID:12904852).
9. Fernández AL, García-Bengochea JB, Alvarez J, González Juanatey JR. Biochemical markers of myocardial injury in the pericardial fluid of patients undergoing heart surgery. *Interact Cardiovasc Thorac Surg* 2008 May;7(3):373-7. (PMID:18258649).
10. Ooi M, Cooper A, Lloyd G, Jackson G. A study of lipid profile before and after coronary artery bypass grafting. *Br J Clin Pract* 1996 Dec;50(8):433-5. (PMID:9039713).
11. Sirvinskas E, Andrejaitiene J, Raliene L, et al. Cardiopulmonary bypass management and acute renal failure: risk factors and prognosis. *Perfusion* 2008 Nov;23(6):323-7. (PMID:19454560).
12. Fong JJ, Sylvia L, Ruthazer R, Schumaker G, Kcomt M, Devlin JW. Predictors of mortality in patients with suspected propofol infusion syndrome. *Crit Care Med* 2008;36:2281-7. (PMID:18664783).