



Turkish Journal of Geriatrics
DOI: 10.31086/tjgeri.2020.164
2020; 23(2): 283-290

- Meltem ÖZDEN YÜCE¹
- Selman ARSLAN¹
- Gözde IŞIK¹
- Orhan Fahri DEMİR²

CORRESPONDANCE

Meltem ÖZDEN YÜCE
Ege University, School of Dentistry, Oral
and Maxillofacial Surgery Department, İzmir,
TURKEY.

Phone: +905323284998
e-mail: meltemozdn@hotmail.com

Received: February 19, 2020
Accepted: April 24, 2020

¹ Ege University, School of Dentistry, Oral and
Maxillofacial Surgery Department, İzmir,
TURKEY.

² Ege University, School of Medicine, Plastic
and Reconstructive Surgery Department,
İzmir, TURKEY.

CASE REPORT

PATHOLOGICAL MANDIBULAR ANGLE FRACTURE: SPONTANEOUS HEALING IN A CASE OF OSTEOMYELITIS AFTER THIRD MOLAR EXTRACTION

ABSTRACT

Late pathological fractures of the mandible associated with the extraction of an impacted third molar and osteomyelitis of the jaw feature rarely in the scientific literature. Indeed, most information on the subject is to be found in the form of case reports. Fractures of this kind may occur in regions where the bone has weakened because of an underlying pathological process, which has developed slowly. Predisposing factors of this complication are believed to be multifactorial but, in the older age group, reduced bone elasticity, bone atrophy, risk of osteoporosis, and potential of tooth ankylosis can weaken the mandible, possibly increasing the rate of fractures. In this study, we report a case of chronic osteomyelitis with a mandibular angle fracture in an elderly male as a rare complication of an odontogenic cystic lesion associated with the extraction of a mandibular third molar. Spontaneous healing occurred with the use of an antibiotic therapy until the second surgical intervention. Attention is focused on the possible risk indicators and preventive measures.

Key Words: Fractures, Spontaneous; Tooth Extraction; Fracture Healing; Geriatric Dentistry.

INTRODUCTION

Surgical extraction of impacted mandibular third molars is generally a safe procedure in the oral surgery department but it can occasionally be accompanied by complications. The most severe and rare complication of impacted third molar extraction is mandibular fracture, which can occur during or after the surgical procedure, usually within the first four weeks after the extraction. The risk factors of this complication are believed to be multifactorial, and the presence of local bone lesions is a predisposing risk factor because of the weakening of the mandible (1-3).

Osteomyelitis is an infection and inflammation associated with bone structures and can occasionally lead to serious complications, such as pathological fractures. It can result from the direct inoculation of micro-organisms due to trauma or surgery. The slow progression of symptoms following the extraction of a third molar should be closely monitored, both clinically and radiographically, to prevent this complication (4).

In this study, we report the rare case of a mandibular angle fracture in a 69-year-old male, 18 weeks after the development of an odontogenic cystic lesion associated with the extraction of an impacted third molar. We go on to discuss possible risk indicators and the association between osteomyelitis of the jaw and pathological fracture after the extraction of an impacted third molar.

CLINICAL REPORT

A 69-year-old man was referred to the Oral and Maxillofacial Surgery department of Ege University for evaluation and treatment of an odontogenic cystic lesion associated with the impacted mandibular left third molar. The patient had no systemic complaints, and routine laboratory tests were normal. The clinical evaluation revealed an expanded swelling of the left mandibular body, with no associated cervical lymphadenopathies,

and chronic and uncontrolled periodontitis. In addition, panoramic radiography showed a well-defined radiolucent lesion surrounding the impacted third molar, with insufficient distance between the lesion and the angle of the mandible (Figure 1).

Based on clinical and radiological findings, the lesion was suspected to be a dentigerous cyst; therefore, surgical treatment for removal of the affected tooth and cystic lesion was planned. The patient was informed of the surgical protocol and a signed consent form was obtained. The surgery was performed under local anesthesia. The mandible was approached via the intra-oral access. The lesion was completely excised, and the impacted tooth was extracted (Figure 2). The surgically-removed enucleated material was sent for histopathologic examination, which confirmed the diagnosis of dentigerous cyst. The patient was scheduled for regular follow-ups.

After 18 postoperative weeks, the patient presented with an expanding swelling of the left mandibular body and complained of severe pain, trismus, and fever. On applying pressure to the operation site, slight seropurulent exudates were observed in the clinical examination. The post-extraction panoramic radiograph revealed the presence of a complete fracture zone without displacements in the left angle of the mandible (Figure 3). Cone-beam computed tomography (CBCT) revealed a fracture line in the left angle of the mandible where the surgery was performed (Figure 4). The pre-diagnosis was osteomyelitis of the mandible with a pathological fracture secondary to the surgical extraction of the left mandibular third molar. Based on the clinical case history, surgical treatment was planned, including sequestrectomy, curettage, and fixation of the fractured fragments under general anesthesia. Before the surgery, moxifloxacin (400 mg every 24 h for seven days) and metronidazole (500 mg every 8 h for seven days) were prescribed to the patient.



Figure 1. A well-defined radiolucent lesion surrounding the impacted third molar with insufficient distance between the lesion and the angle of the mandible.

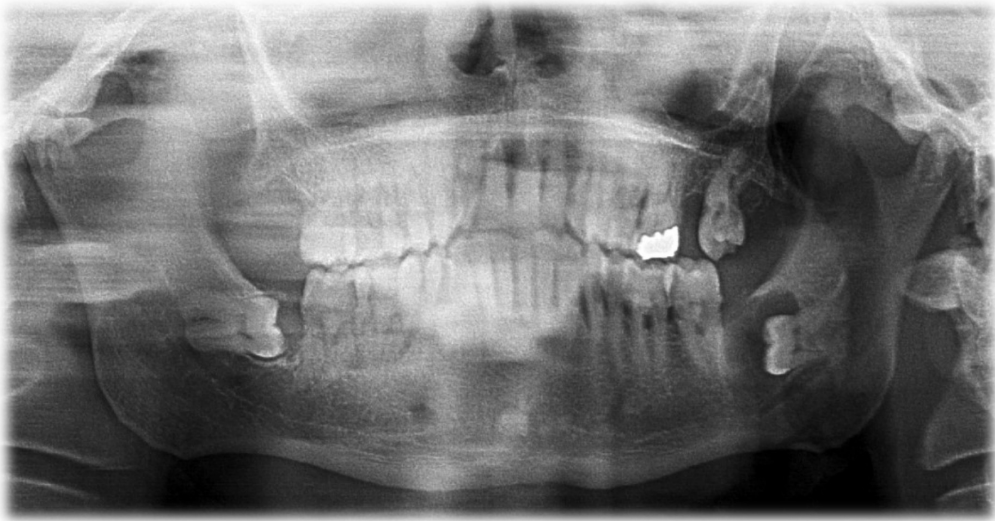


Figure 2. Post-operative panoramic image of the patient after excision of the odontogenic cystic lesion and extraction of the impacted tooth.

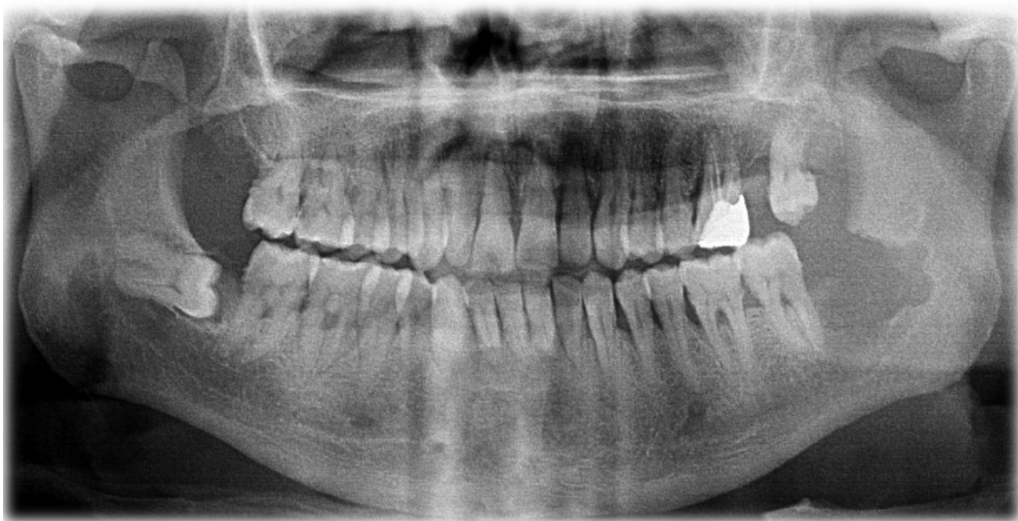
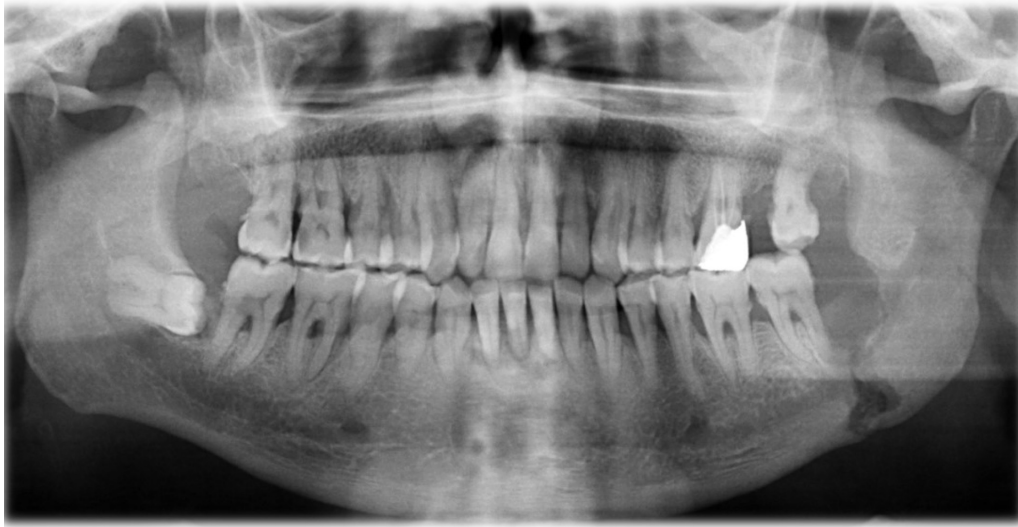
Figure 3. After 18 post-operative weeks, presence of a complete fracture zone without displacements in the left angle of the mandible.



After one postoperative month, on the operation day, the mandible was approached via the extra-oral access under general anesthesia; however, the fracture line was completely healed spontaneously, and the fracture was immobile (Figure 5). Before surgery no additional periodontal or dental infection or inflammation existed. The area was curated carefully, and the patient was scheduled for frequent routine follow-ups.

DISCUSSION

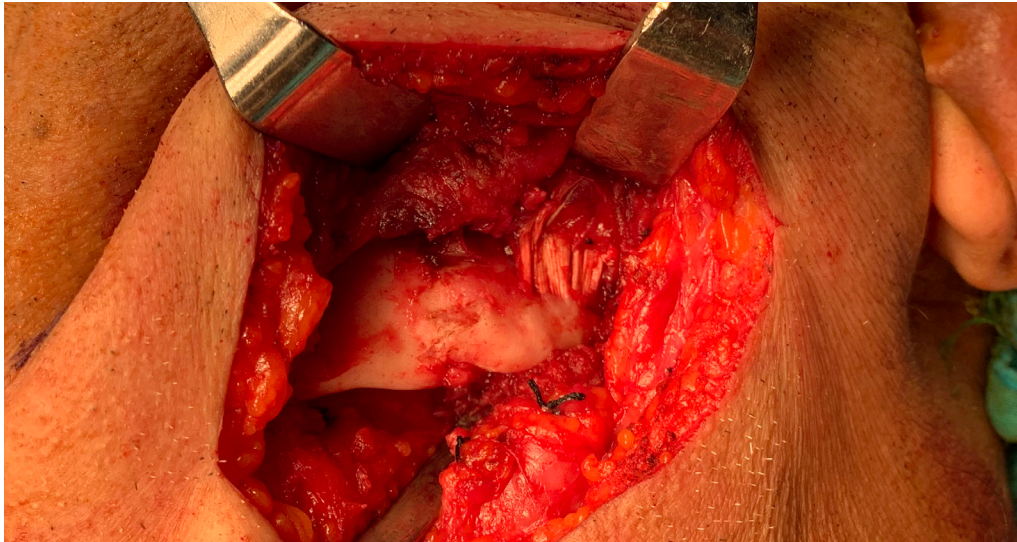
Mandibular angle fracture associated with the extraction of an impacted third molar is a rare complication and is considered multifactorial, with factors including: age, sex, degree of impaction, relative volume of the tooth in the jaw, pre-existing infections or bone lesions, failure to maintain a soft diet in the early postoperative period, and surgical technique. It may occur as an immediate

or a late complication, usually within the first four weeks after the extraction (3-5).

Deeply impacted third molars have a significant impact on risk due to the greater volume of bone which is required to be removed during the surgery. Pre-existing bone lesions, such as odontogenic cysts, may easily diminish the strength of the bone and predispose to fractures (5). These lesions are more frequently found in patients aged 40 years or older, and special care should be taken when the third molar is associated with pathological lesions in elderly patients (6). Pippi et al. recommended the use of a miniplate to avoid postoperative mandibular fractures if an odontogenic cystic lesion is associated with a deeply impacted tooth (7). In cases of predisposing factors for this complication, all preventive measures should be considered before and during the surgery, such as sectioning the tooth, using correct instrumentation, and avoiding uncontrolled excessive forces (7,8). The



Figure 5. Spontaneous healing of fracture zone.



case presented here involved a higher possibility of mandibular fractures due to the large volume of bone removal and weakening of the mandible. For this reason, the tooth was sectioned to minimize bone removal after excision of the cystic lesion. However, no lingual cortical involvement was found with the impacted tooth and the use of a miniplate was not required.

Weakening of the mandible due to a decrease in its bone elasticity through aging may also play a role in the occurrence of mandibular fractures (9). Moreover, in the older age group, reduced bone elasticity, bone atrophy, risk of osteoporosis, and potential for tooth ankylosis weaken the mandible, possibly increasing the rate of fractures (10). In addition, late fractures usually occur during the second or third postoperative week, resulting from a high level of biting forces during mastication, especially in men aged over 40 years with complete dentition (5). Also, the risk to men

is greater due to the increased possibility of trauma (8,10). In accordance with the findings of the previously-mentioned studies, the patient in this case was a 69-year-old male, with complete dentition, and a fully impacted third molar associated with an odontogenic cystic lesion. On the panoramic and CBCT scans obtained before surgery, the impaction was shown to be deep, with an insufficient distance from the apex of the socket to the inferior border of the mandible.

Surgical trauma, pulpal, and/or periodontal infections are predisposing factors for osteomyelitis. Pathological fractures due to a weakened bone are a serious complication of osteomyelitis (3). As the patient in this case was visually impaired, he was unable to maintain his oral hygiene at an adequate level postoperatively and he had localized periodontal infection at the surgical area. Therefore, after 18 postoperative weeks, it was found he had developed

osteomyelitis of the mandible with a pathological fracture secondary to the surgical extraction of the left mandibular third molar.

Bone healing can occur through a direct or indirect mechanism. Direct bone healing occurs under conditions of absolute stability, while indirect bone healing is the only natural method of fracture healing. Spontaneous bone healing can be regarded as indirect bone healing, which can sometimes occur with untreated jaw fractures (11). In this case, spontaneous healing occurred in the last month when the patient was receiving antibiotic therapy for osteomyelitis. During the second operation, we found natural and spontaneous healing of the fracture. Spontaneous healing may have occurred because of the patient's Complete dentition and his dental occlusion avoiding displacement produced by the masticatory muscles.

The case presented here has some limitations because the patient was not evaluated with

respect to bone mineral density (BMD) values, which are used to measure bone strength. Post menopausal women have a statistically significant risk of osteoporosis and elderly men, aged over 60, also have a high risk of developing the disease (12). Before surgical intervention, it is necessary in both men and women to measure oral bone variable indexes such as BMD, as it is a significant predictor of fracture especially in the risk group.

Although they are rare occurrences, mandibular fractures caused by extraction of a deeply impacted lower third molar, and corresponding preventive techniques, are frequently reported in the literature. To prevent this complication, or to manage it professionally when it does occur, clinical and radiological evaluations should be performed meticulously before surgery, especially in the case of an elderly population. Furthermore, it is important that patients in the risk group are followed up at regular intervals after the procedure.

REFERENCES

1. Xu JJ, Teng L, Jin XL, et al. Iatrogenic Mandibular Fracture Associated with Third Molar Removal After Mandibular Angle Osteotomy. *J Craniofac Surg* 2014;25(3):263–265. (PMID:24820729).
2. Cankaya AB, Erdem MA, Cakar S, et al. Iatrogenic Mandibular Fracture Associated with Third Molar Removal. *Int J Med Sci* 2011;8(7):547–553. (PMID:21960746).
3. Joshi A, Goel M, Thorat A. Identifying the risk factors causing iatrogenic mandibular fractures associated with exodontia: a systemic meta-analysis of 200 cases from 1953 to 2015. *Oral Maxillofac Surg* 2016;20(4):391–396. (PMID:27660249).
4. Yamamoto S, Taniike N, Yamashita D, et al. Osteomyelitis of the Mandible Caused by Late Fracture following Third Molar Extraction. *Case Rep Dent* 2019. (PMID:31467733).
5. Woldenberg Y, Gatot I, Bodner L. Iatrogenic mandibular fracture associated with third molar removal. Can it be prevented? *Med Oral Patol Oral Cir Bucal* 2007;12(1):70–72. (PMID:17195834).
6. Lysell L, Rohlin M. A study of indications used for removal of the mandibular third molar. *Int J Oral Maxillofac Surg* 1988;17:161–164. (PMID:3135340).
7. Pippi R, Solidani M, Broglia S, et al. Prevention of Mandibular Fractures Caused by Difficult Surgical Extractions: Report of a Borderline Case. *J Oral Maxillofac Surg* 2010;68:1162–1165. (PMID:20188450).
8. Bodner L, Brennan PA, McLeod NM. Characteristics of iatrogenic mandibular fractures associated with tooth removal: review and analysis of 189 cases. *Br J Oral Maxillofac Surg* 2011;49:567–572. (PMID:20947226).
9. Wagner KW, Otten JE, Schoen R, Schmelzeisen R. Pathological mandibular fractures following third molar removal. *Int J Oral Maxillofac Surg* 2005;34:722–6. (PMID:15878820).
10. Ethunandan M, Shanahan D, Patel M. Iatrogenic mandibular fractures following removal of impacted



third molars: an analysis of 130 cases. Br Dent J 2012;212(4):179–184. (PMID:22361547).

11. Guerrissi JO. Fractures of Mandible: Is Spontaneous Healing Possible? Why? When? J Craniofac Surg 2001;12(2):157–66. (PMID:11314627).
12. Ferreira Leite A, de Souza Figueiredo PT, Ramos Barro F, et al. Relationships between mandibular cortical indexes, bone mineral density, and osteoporotic fractures in Brazilian men over 60 years old. Oral Surg Oral Med Oral Pathol Oral Radiol Endod 2011;112(5):648–56. (PMID: 21903429).