

Bahri TEKER¹
Mehmet AĞIRMAN²
Tuğrul ÖRMECİ³
Mehmet TEZER⁴
Ali MERT⁵
Engin ÇAKAR²

İletişim (Correspondance)

Mehmet AĞIRMAN
İstanbul Medipol University, Department of Physical
Medicine and Rehabilitation, ISTANBUL

Tlf: 444 70 70
e-posta: mehmetagirman@yahoo.com

Geliş Tarihi: 23/08/2014
(Received)

Kabul Tarihi: 29/09/2014
(Accepted)

¹ Nisa Hospital, Infectious Diseases and Clinical
Microbiology ISTANBUL

² Istanbul Medipol University, Department of Physical
Medicine and Rehabilitation ISTANBUL

³ Istanbul Medipol University, Radiology ISTANBUL

⁴ Istanbul Medipol University, Orthopedics and
Traumatology ISTANBUL

⁵ Istanbul Medipol University, Internal Medicine
ISTANBUL



CASE REPORT

PARAPLEGIA IN AN ELDERLY PATIENT DUE TO POTT'S DISEASE

ABSTRACT

Spinal tuberculosis (Pott's disease) is still an important problem in many countries and may result in severe neurological deficits. Pott's paraplegia can occur in the early period of the disease or many years later. Pott's disease usually occurs in the thoracic vertebrae and may cause neurological symptoms as a consequence of bone destruction and spinal cord compression. In this article, we present the case of a 73-year-old diagnosed with Pott's paraplegia who was referred to our clinic with back pain. He had been previously diagnosed with pulmonary tuberculosis and had received anti-TB therapy. After five weeks of an intensive rehabilitation program, the patient could walk independently and was discharged with minimal dependency. We conclude that there should be more awareness of the possibility of non-traumatic spinal cord injuries in elderly patients.

Key Words: Paraplegia; Tuberculosis, Spinal; Rehabilitation; Aged.



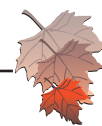
OLGU SUNUMU

YAŞLI BİR HASTADA POTT HASTALIĞINA BAĞLI GELİŞEN PARAPLEJİ OLGUSU

Öz

Spinal tüberküloz (Pott hastalığı) günümüzde halen bir çok ülkede önemli bir sağlık sorunudur ve ağır nörolojik kayıplara neden olabilmektedir. Pott hastalığına bağlı parapleji, hastalığın erken dönemlerinde yada yıllar sonra ortaya çıkabilmektedir. Genellikle torasik vertebralarda ortaya görülmekte, kemik yıkımı ve spinal kord basısına bağlı olarak da nörolojik bulgulara sebep olabilmektedir. Bu makalede, kliniğimize bel ağrısı ile yönlendirilen, Pott parapleji tanısı konan 73 yaşındaki bir hasta sunulmaktadır. Hasta daha öncesinde pulmoner tüberküloz tanısı ile takip edilmekte ve anti-tüberküloz tedavi almaktaydı. Hasta beş haftalık yoğun rehabilitasyon programından sonra bağımsız olarak yürüyebildi ve minimal bağımlı olarak taburcu edildi. Sonuç olarak yaşlı hastalarda travmatik olmayan spinal kord yaralanmaları ihtimali konusunda dikkatli olunmalıdır.

Anahtar Sözcükler: Parapleji; Spinal Tüberküloz (Pott hastalığı); Rehabilitasyon; Yaşlı.



INTRODUCTION

Tuberculosis (TB) is divided into two sub-groups, pulmonary and extra-pulmonary, according to clinical form. It remains a serious problem in developing countries. Bone and joint tuberculosis is most frequently seen in the spine and includes 1% of all tuberculosis cases (1). Pott's disease (tuberculosis of the spine-spondylodiscitis) is one of the most important sources of non-traumatic spinal cord lesions, after spinal tumors (2). Pott's disease usually occurs in the thoracic vertebrae and may cause neurological symptoms as a consequence of bone destruction and spinal cord compression. Although the incidence decreases with age, trauma is still the most common reason for spinal cord injuries in elderly people (3). In this article, we report a case with non-traumatic spinal cord injury associated with tuberculosis spondylodiscitis and a successful rehabilitation outcome after surgery.

CASE

A 73-year-old male patient who had had back pain for three months was referred to our clinic from the infectious diseases department. He had been previously diagnosed with pulmonary tuberculosis and had been given anti-TB therapy (isoniazid, rifampicin, pyrazinamide and ethambutol) for five months. He experienced an increase in back pain with motion and walking. There was tingling and numbness in both legs. Over the past month, he had complained of difficulty walking and bilateral knee joint contractures. On sensory examination, he had bilateral L2, L3, L4 and L5 hypoesthesia, and anesthesia in the S1 dermatome with pin prick and light touch tests. On motor examination, bilateral L2 and L3 muscle strength was 2/5, and L4, L5 and S1 muscle strength was 1/5. In laboratory analyses, sedimentation was 32, Hb was 13.8 g/dL, WBC was 7.500 mm³, platelets were 317,000 mm³, and CRP was 1.68 mg/L. Pathological reflexes included bilateral clonus and he had 30° contractures in both knees. In magnetic resonance imaging (MRI), there were compression fractures in the D11 and D12 vertebral bodies, an epidural abscess located on the anterior epidural space and a spinal cord injury at this level (figure 1, figure 2). The patient was operated for decompression and posterior fusion. The culture of the operated material was positive for *M. Tuberculosis*. After surgery, the patient was hospitalized in the physical medicine and rehabilitation clinic. On initial examination after surgery, the patient's ASIA classification was C. The patient was mobilized by turning on both sides, and isomet-

ric muscle strength exercises were started for the lower limb, abdominal and pelvic muscles after the first postoperative day. The patient was seated as soon as possible and a corset was used while sitting and standing. Respiratory exercises, passive range of motion, and active and active-assistive isotonic strengthening exercises were done and electrical stimulation was applied to the back and limb muscles. After a five-week intensive rehabilitation program, the patient could walk independently with a walker device. His Barthel index was 70 (moderate dependency) at the beginning of treatment and rose to 95 (minimal dependency) by the end of treatment. At discharge, the patient's ASIA classification was D.

DISCUSSION

Spinal tuberculosis is still an important problem in many countries and may result in severe neurological deficits. Pott's paraplegia can occur in the early period of disease or many years later (4). Rehabilitation outcomes and improvement after surgery are better for early onset Pott's paraplegia than for late onset (5). Therefore, we report this case of our patient whose rehabilitation was successful and who recovered well from paraplegia.

Ten percent of patients with spinal tuberculosis may develop paraplegia (5). If neurological symptoms present after spinal tuberculosis, early diagnosis of spinal cord injury is important and a spinal cord compression should be suspected on examination and must be confirmed by radiologic imaging.

In our case, the patient complained of back pain and difficulty walking due to lower limb weakness. According to the literature, fever may occur frequently, in addition to pain and neurological deficits (6). To confirm the diagnosis, radiological images (especially MRI) are useful. Direct radiography is positive for only one third of patients (7). In our patient's direct radiography, the destruction of anterior contours and also increased radiolucency of vertebral bodies were seen, and in the magnetic resonance investigation compression and myelomalacia were seen.

The treatment of Pott's disease for cases who have a neurological deficit and severe spinal deformity is early surgical decompression and fusion. A radiological finding of cord compression alone is not an indication for emergency surgery. If there are light and non-progressive neurological signs, most authors suggest conservative management (1,8,9). Therefore, early surgical intervention in selected patients provides better clinical recovery with intensive rehabilitation. Functional



recovery varies between 50% and 90%, according to different authors (10). In a study of 47 patients, early and long-term (6 month) rehabilitation after surgery showed good improvements in mobility, motor and functional scores of patients both with and without surgery (7). In a study that evaluated non-traumatic spinal cord injury due to Pott's paraplegia or other causes, Gupta et al. reported significant functional recovery after a rehabilitation period (2).

The primary cause of spinal cord injury in elderly patients is trauma caused by falls. The absence of trauma in etiologies such as infections may delay the diagnosis; this puts the patient at more risk for neurological deficits and reduced quality of life. Elderly people have less physiological capacity than younger people. Even though the spinal cord injury may be of the same severity, expected rehabilitation outcomes are poorer in elderly individuals (3).

According to the literature, in cases of paraplegia for non-traumatic causes in elderly people, we can expect a longer hospitalization time and rehabilitation period than for younger people (11). To our knowledge, there are no published studies that specifically address Pott's paraplegia in elderly patients. In this case, early treatment increased the health outcomes of our patient. In the rehabilitation program, he was mobilized as soon as possible to prevent pressure sores. Isometric and isotonic exercises were performed in the early period, as tolerated. He improved after five weeks of intensive rehabilitation and was discharged with minimal dependency.

In conclusion, Pott's disease is still widespread in developing countries and can cause paraplegia due to spinal cord injury. Especially in elderly patients, there should be more awareness of non-traumatic spinal cord injuries. With early diagnosis, surgical treatment and intensive rehabilitation, patients' functional status can be successfully improved.

REFERENCES

1. Kalita J, Misra UK, Mandal SK, Srivastava M. Prognosis of conservatively treated patients with Pott's paraplegia: Logistic regression analysis. *J Neurol Neurosurg Psychiatry* 2005;76(6):866-8. (PMID:15897514).
2. Gupta A, Taly AB, Srivastava A, Murali T. Non-traumatic spinal cord lesions: epidemiology, complications, neurological and functional outcome of rehabilitation. *Spinal Cord* 2009;47(4):307-11. (PMID:18936767).
3. Groah SL, Charlifue S, Tate D, et al. Spinal cord injury and aging: challenges and recommendations for future research. *Am J Phys Med Rehabil* 2012;91(1):80-93. (PMID:21681060).
4. Luk KD. Tuberculosis of the spine in the new millennium. *Eur Spine J* 1999;8(5):338-45. (PMID:10552315).
5. Zhang Z. Late onset Pott's paraplegia in patients with upper thoracic sharp kyphosis. *Int Orthop* 2012;36(2):381-5. (PMID:21656306).
6. Yen HL, Kong KH, Chan W. Infectious disease of the spine: outcome of rehabilitation. *Spinal Cord* 1998;36(7):507-13. (PMID:9670388).
7. Nas K, Kemalöglü MS, Cevik R, et al. The results of rehabilitation on motor and functional improvement of the spinal tuberculosis. *Joint Bone Spine* 2004;71(4):312-6. (PMID:15288857).
8. Patil SS, Mohite S, Varma R, Bhojraj SY, Nene AM. Non-surgical management of cord compression in tuberculosis: A series of surprises. *Asian Spine J* 2014;8(3):315-21. (PMID:24967045).
9. Nene A, Bhojraj S. Results of nonsurgical treatment of thoracic spinal tuberculosis in adults. *Spine J* 2005;5(1):79-84. (PMID:15653088).
10. Zaoui A, Kanoun S, Boughamoura H, et al. Patients with complicated Pott's disease: Management in a rehabilitation department and functional prognosis. *Ann Phys Rehabil Med* 2012;55(3):190-200. (PMID:22445109).
11. Irwin ZN, Arthur M, Mullins RJ, Hart RA. Variations in injury patterns, treatment, and outcome for spinal fracture and paralysis in adult versus geriatric patients. *Spine (Phila Pa 1976)* 2004;29(7):796-802. (PMID:15087803).