

Sibel SÜZEN ÖZBAYRAK¹
Murat ULUDAĞ²
Mustafa ÖZBAYRAK³
Ülkü AKARIRMAK²

Correspondance

Sibel SÜZEN ÖZBAYRAK
Haydarpaşa Numune Training and Research Hospital,
Physical Medicine and Rehabilitation Clinic, İSTANBUL

Phone: 0216 542 32 32
e-mail: sibels62@yahoo.com

Received: 09/02/2016

Accepted: 26/04/2016

¹ Haydarpaşa Numune Training and Research Hospital,
Physical Medicine and Rehabilitation Clinic, İSTANBUL

² İstanbul University, Cerrahpaşa Medical Faculty,
Department of Physical Medicine and Rehabilitation,
İSTANBUL

³ İstanbul University, Cerrahpaşa Medical Faculty,
Department of Radiology, İSTANBUL



CASE REPORT

SPLIT CORD MALFORMATION: BECOMING FIRST SYMPTOMATIC IN AN ELDERLY PATIENT AS A NECK PAIN AND SCOLIOSIS

ABSTRACT

Split cord malformation represents a closed neural tube defect in which the spinal cord splits into two parts. The majority of cases symptoms onset during childhood. Although it can occur at any level, malformation is more commonly detected in lower thoracic and upper lumbar regions. The case reported herein is unique; in contrast to other split cord malformation patients our case was diagnosed in adulthood, with the condition manifesting at the level of the cervical vertebrae, and with no neurological deficit and concomitant neurocutaneous symptoms; but the vertebral anomalies such as scoliosis, hemivertebra and vertebral fusion existing all together. We emphasize the need to consider split cord malformation in the differential diagnosis of elderly patients presenting with neck pain and scoliosis and also we mention that conservative treatment should be preferred in patients without progressive neurologic deficit.

Key Words: Spinal Cord/Abnormalities; Neck Pain, Scoliosis, Cervical Vertebrae; Aged; Congenital Abnormalities.



OLGU SUNUMU

İLERİ YAŞTA BULGU VEREBİLEN, BOYUN AĞRISI VE SKOLYOZUN NADİR GÖRÜLEN BİR NEDENİ: SPLIT KORD MALFORMASYONU

Öz

Split kord malformasyonu, spinal kordun iki parça halinde bulunduğu kapalı bir nöral tüp defektidir. Olguların çoğu çocukluk çağında bulgu vermektedir. Herhangi bir vertebra seviyesinde görülebilirken en sık alt torasik ve üst lomber bölgede görülmektedir. Erişkin yaşta split kord malformasyonu tanısı alması, lezyonun nadir bir bölge olan servikal bölgede görülmesi, herhangi bir nörolojik defisit saptanmaması, nörokutanöz bir belirtinin eşlik etmemesi ve skolyoz, hemivertebra ve vertebra füzyonunun birlikte görülmesi nedeniyle nadir görülen bir olgu sunulacaktır. Fizik tedavi kliniğinde sıkça karşılaştığımız boyun ağrısı ve skolyozun nadir bir sebebi olarak split kord malformasyonu ayırıcı tanıda bulunmalı ve asemptomatik ilerleyici nörolojik defisiti olmayan hastalarda konservatif tedavi seçeneği düşünülmelidir.

Anahtar Sözcükler: Split Kord Malformasyonu; Boyun Ağrısı; Skolyoz; Servikal Vertebra; Yaşlı; Doğumsal Anomaliler.



INTRODUCTION

Split cord malformation represents a closed neural tube defect in which the spinal cord splits into two parts. There are two types of split cord malformation. In the more-common Type 1 SCM, the spinal cord splits into two parts by bony and fibrocartilaginous structures, with each part surrounded by the dural sac. In Type 2 SCM, although not divided by the bony septum the spinal cord is split by the intradural septum, with both parts situated within a single dural sac (1,2). Neurologic deficit, neurocutaneous symptoms and vertebral anomalies can frequently accompany to split cord malformation.

The case reported herein is unique; in contrast to other split cord malformation patients our case was diagnosed in adulthood, with the condition manifesting at the level of the cervical vertebrae, and with no neurological deficit and concomitant neurocutaneous symptoms but the vertebral anomalies such as scoliosis, hemivertebra and vertebral fusion existing all together in our case.

CASE

A 65-year-old female presented with neck pain of 20-year duration. Pain severity increased intermittently. In the previous month, neck pain severity had increased, did not respond to medical treatment, and was radiating to the right arm with accompanying numbness and hypoesthesia. The pain was mechanical in origin and thus increased during neck movement. The patient also complained of fatigue and tiredness.

Right-sided scoliosis and an anteflexed posture were revealed by physical examination (Figure 1,2). A decrease in dorsal kyphosis, and lumbar lordosis, were detected, in addition to prominent abdominal obesity. There was tenderness in the cervical spinous processes upon palpation. Neck range of motion was restricted and painful; range of motion was also restricted in the right shoulder, which was painful during physical examination. During neurological examination, the muscle strength of the upper and lower extremities was rated as 5/5. The sensory examination was also intact. Deep tendon reflexes were globally normoactive. The Babinski test was negative.

Anteroposterior cervical radiography revealed osteophytes of the corpus end plates, fusion abnormalities in cervicothoracic region and degenerative changes were detected, in addition to irregularity in bony structures of the cervical region (Figure 3). In cervicothoracic magnetic resonance imaging (MRI), thoracic kyphosis and lumbar lordosis were decreased, with degenerative changes and hemivertebra and fusion in the

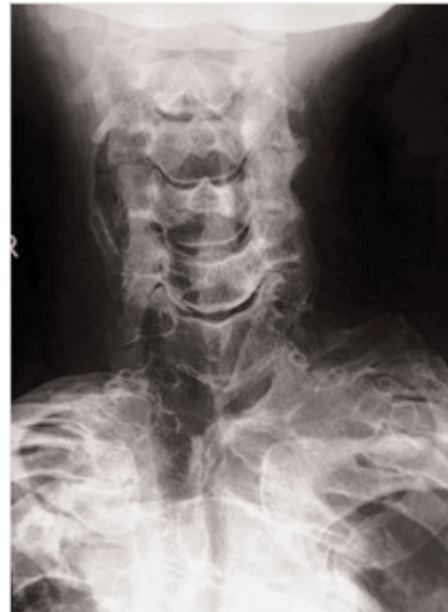

Figure 1— Scoliosis and pili asymmetry are seen on the spine of the patient.

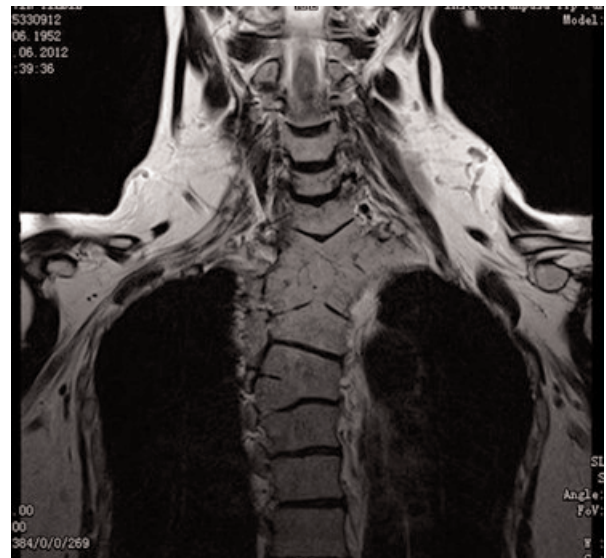


Figure 2— Rotoscoliosis on coronal plain radiography of the lumbar spine.

corpus of the C6, C7, T1, and T2 vertebrae (Figure 4). Partial split cord malformation and dural sac ectasia were observed in the spinal cord, at the level of the C6 and C7 vertebrae (Figure 5). Bulging and slight spinal cord compression was pre-

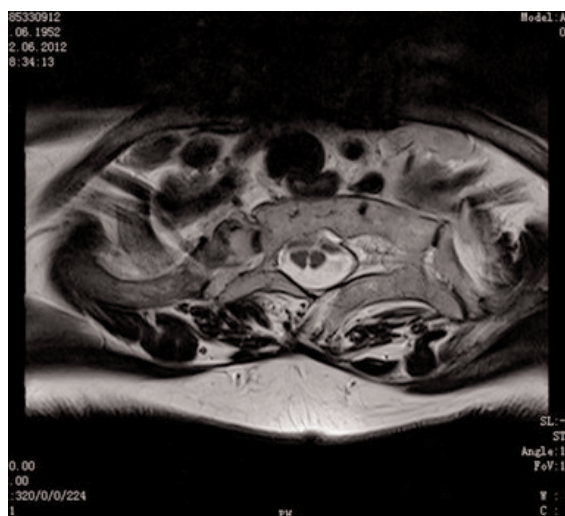


Figure 3— Coronal plain radiography of the cervical spine shows fusion abnormality on cervicothoracic junction.

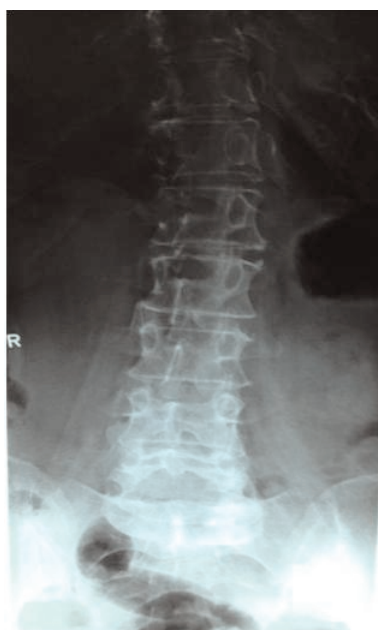

Figure 4— The coronal T2-weighted magnetic resonance image shows multiple fusion abnormalities on lower cervical and upper thoracic vertebrae.

sent at the level of the C3-4 and C5-6 vertebrae, respectively. Wide-based central protrusion and spinal cord compression was detected at the level of the C4-5 vertebrae.

Conservative treatment including non-steroidal anti-inflammatory drugs, physical therapy and cervical isometric

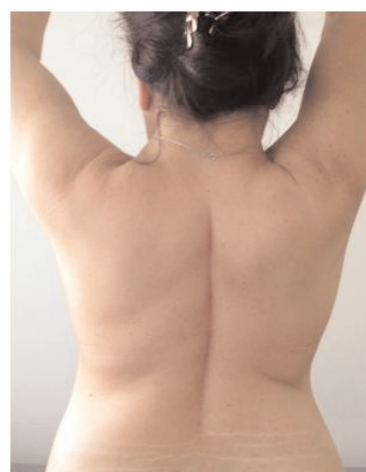


Figure 5— The axial T2-weighted magnetic resonance image shows split cord at the same level.

exercise were started. Cervical collar was given and daily life activities were checked and regulated. After 3 weeks of evaluation, the neck pain of the patient was decreased significantly.

DISCUSSION

Split cord malformation (SCM) represents a closed neural tube defect in which the spinal cord splits into two parts. In the more-common Type 1 SCM, the spinal cord splits into two parts by bony and fibrocartilaginous structures, with each part surrounded by the dural sac. In Type 2 SCM, although not divided by the bony septum the spinal cord is split by the intradural septum, with both parts situated within a single dural sac (1). According to recent reports, Type 1 and Type 2 SCM can also co-occur, although this is rare, at < 1% of all SCM cases (2). In our patient, partial split cord malformation was observed at the C6-7 level. Two spinal cord splits were detected in one dural sac, with the case classified as Type 2 SCM.

Spinal cord malformation is a congenital malformation accounting for 4% of all congenital spinal defects.

Although it can occur at any level, malformation is more commonly detected in lower thoracic and upper lumbar regions (3). Of all cases, 47% of malformations occur in the lumbar region, with 27% occurring in the thoracolumbar region, 23% in the thoracic region and 1.5% in both the sacral and cervical regions (4). In our patient the cervical region was affected, which is rarely reported.



Malformations can originate from the midline anterior septum of the corpus vertebrae, or from posterior vertebral structures; more commonly, it intersects the entire spinal canal.

Although in the majority of cases symptoms onset during childhood, several adult-onset cases have also been reported (5-11). Our patient was a 65-year-old female experiencing significant neck and back pain for 20 years; because her symptoms onset at approximately age 40, this case report is unique. In 1994, Kennedy reviewed 60 patients, of whom nine displayed symptoms when > 20 years of age; the mean age at diagnosis was 5 years. Due to recent advances in imaging techniques, the number of older-age case reports has increased.

In the majority of split cord malformation patients, symptoms are due to a tethered cord. Weakness in the lower extremities, back pain, urinary and fecal incontinence and scoliosis can accompany the condition (12-14). Abnormality in the neurological system such as an increase or inequality in deep tendon reflexes, can also occur. In our patient, aside from numbness and tingling radiating to the right arm, and a positive plantar reflex in the right foot, no neurological deficits were detected.

Right-sided scoliosis was also observed. Split cord malformation can occur in congenital scoliosis: the probability of co-occurrence of vertebral and spinal cord anomalies in congenital scoliosis is 40%, and includes spinal dysraphism (10%), diastematomyelia (5%), SCM, a tethered cord, Arnold-Chiari malformation, Sprengel's deformity, and Klippel-Feil Syndrome (12-14).

Several dermatological signs indicate spinal dysraphism, such as an increase in hair growth over the lesion, lipoma, and scar tissue. In our patient no cutaneous lesion was detected upon inspection.

Neuroenteric cysts, hemangioma, and meningocele are other commonly observed anomalies.

Club foot, atrophic thigh muscles and leg length discrepancies can also accompany spinal dysraphism. Dermatological involvement and vertebral anomalies are observed more frequently in Type 1 SCM. These vertebral anomalies include hemivertebra, butterfly vertebra and fusion of the laminae of neighboring vertebrae.

The majority of patients are diagnosed due to signs and symptoms of a tethered cord or scoliosis. Typically, a bone or fibrocartilaginous septum splits the spinal cord into two parts; hydromyelia is also frequently observed. However, in Type 2 SCM symptoms are usually mild, or patients may be asymptomatic. In our patient, MRI revealed hemivertebra and fusion in the corpus of the C6, C7, T1 and T2 vertebrae.

Computerized tomography is the preferred method of diagnosis, achieving superior detection of bone pathology (including intraspinal deformity) compared with MRI myelography (5,7,9). In our patient, cervical radiography revealed abnormalities in bony structures, including congenital anomalies and extra cervical ribs. To achieve detailed evaluation of the pathology, whole spinal MRI was performed, with SCM subsequently diagnosed.

Conservative treatment should be preferred for asymptomatic patients without progressive neurologic deficits (6,7). Electrotherapy, and stretching and strengthening exercises, were recommended for 1 month for our patient, which represents a conservative treatment. Significant improvement in symptoms was subsequently observed, but restricted cervical range of motion was still present. The patient was discharged and advised to frequently attend follow-ups.

Surgery should be the treatment of choice in adults with split cord malformation only when neurologic deficits due to spinal stenosis or a tethered cord are present. There is no indication for prophylactic spur resection in asymptomatic adults. Prior to performing scoliosis surgery in children, spur resection and release of attachments to the spinal cord in the case of a tethered cord, should be performed. Post-operative neurological deficits will otherwise increase due to spinal cord traction (15).

Following spur resection, spur recurrence is rarely observed, with few cases reported in the literature (16). Meningeal residual polyvalent mesenchymal cells may remain in the spinal cord following simple extradural resection of a bony septum, reactivating and thus causing its recurrence.

The case reported herein is unique; in contrast to other split cord malformation patients our patient was diagnosed in adulthood, with the condition manifesting at the level of the cervical vertebrae, and with no neurological deficit, concomitant neurocutaneous symptoms. And also vertebral anomalies such as scoliosis, hemivertebra or vertebral fusion existing all together. We emphasize the need to consider split cord malformation in the differential diagnosis for elderly patients presenting with neck pain and scoliosis.

REFERENCES

1. Pang D, Dias MS, Ahab-Barmada M. Split cord malformation: Part 1: A unified theory of embryogenesis for double spinal cord malformations. *Neurosurgery* 1992;31(3): 451-80. (PMID:1407428).
2. Harwood-Nash DC, McHugh K. Diastematomyelia in 172 children: the impact of modern neuroradiology. *Pediatr Neurosurg* 1990;16:247-51. (PMID:2135195).



3. Kaminker R, Fabry J, Midha R, et al. Split cord malformation with diastematomyelia presenting as neurogenic claudication in an adult. a case report. *Spine* 2000;25(17):2269–71. (PMID:10973414).
4. Birch BD, McCormick PC. High cervical split cord malformation and neurenteric cyst associated with congenital mirror movements: case report. *Neurosurgery* 1996;38:813–15. (PMID:8692403).
5. Hesselink JW, Tans JJ, Hoogland PH. Diastematomyelia presenting in two male adults with low back pain. *Clin Neurol Neurosurg* 1986; 88: 223–6. (PMID:2946506)
6. Kennedy PR. New data on diastematomyelia. *J Neurosurg* 1979;51:355–61. (PMID:469580).
7. Russel NA, Benoit BG, Joaquin AJ, et al. Adult diastematomyelia. *Can J Neurol Sci* 1994;21:72–4. (PMID:8180911).
8. Linn RM, Ford LT. Adult diastematomyelia. *Spine* 1994;19:852–4. (PMID:8202809).
9. English WJ, Maltby JL. Diastematomyelia in adults. *J Neurosurg* 1967;27:260–4. (PMID:6097998).
10. Dale AJ. Diastematomyelia. *Arch Neurol* 1969;20:309–17. (PMID:5766495).
11. Pang D, Wilberger JE. Tethered cord syndrome in adults. *J Neurosurg* 1982;56:32–47. (PMID:7086498).
12. Beals R, Robbins JR, Rolfe B. Anomalies associated with vertebral malformations. *Spine* 1993;18(10):1329–32. (PMID:8211365).
13. Bradford DS, Heithoff KB, Cohen M. Intraspinous abnormalities and congenital spine deformities: a radiographic and MRI study. *J Pediatr Orthop* 1991;11:36–41. (PMID:1988476).
14. McMaster MJ. Congenital scoliosis caused by a unilateral failure of vertebral segmentation with contralateral hemivertebra. *Spine* 1998;23:998–1005. (PMID:9589537).
15. Rothman RH, Simeone FA. *The Spine*. 3rd ed. Philadelphia: W.B. Saunders, 1992, pp 373–89.
16. Pang D, Parrish RG. Regrowth of diastematomyelic bone spur after extradural resection. Case report. *J Neurosurg* 1983;59:887–90. (PMID:6619944).